

## Echocardiography Guided Management of Septic Shock

Walid S. Alhabashy<sup>1\*</sup>  
Rodney Meeke<sup>2</sup>

<sup>1</sup>Department of Anesthesiology and Critical Care Medicine, Cork University Hospital, Cork, Ireland

<sup>2</sup>Anaesthesia Consultant, Cork University Hospital, Cork

### Summary

Septic shock is on top of the highest causes of mortality and morbidity. Recent studies have highlighted the complex cardiovascular system involvement in the septic shock patients. Diastolic dysfunction or heart failure with preserved ejection fraction is correlated with high mortality in patients with septic shock. Diastolic dysfunction emerges from sepsis itself or from vasopressors and inotropes used in the septic shock management due to tachycardia induced short diastolic filling times. Fluids volume, when to start and when to stop is still a challenge in critical settings and should be tailored to variable patient needs. Echocardiography is a growing tool as a non-invasive bedside radiation free easily repeatable tool used in hemodynamic assessment critical care setting.

### Case Presentation

Mr. CC is a 78-year-old man who was referred to our hospital as a case of shock due to a contained rupture of AAA. Intubated, ventilated for an open laparotomy and surgical repair of contained AAA rupture. He was a previously healthy with no medical history or allergies. GA/ETT, Arterial, central venous lines and dialysis catheter were inserted in operating theatre. Initial ABGs: Severe anion gap acidosis due to high lactate (LA), pH 7.1, Arterial Carbon Dioxide tension (PaCO<sub>2</sub>) 5.4, Arterial Oxygen tension (PO<sub>2</sub>) 40, Bicarbonate (HCO<sub>3</sub>) 13 and LA 9.8. Fluid resuscitation 1.5L, laparotomy shows total ischemic colon and tertiary peritonitis. Total colectomy was done and Abdominal Aortic Aneurysm (AAA) was intact with no rupture, patient was moved to General ICU after 3 hours of surgery during which he received 2L of Compound Sodium Lactate (CSL) and Noradrenaline requirements were increasing. On arrival to ICU he was on Noradrenaline 30 mcg/min, Adrenaline 20 mcg/min and still Anuric. pH 7.19, LA 8.9. Initial vital signs: Arterial Blood Pressure (ABP): 113/63 Pulse rate (PR):118 Oxygen saturation (SPO<sub>2</sub>): 100%.

First bedside Echocardiography showed: Sinus tachycardia 118/min, Hyper contractile LV, Small RV, no regional wall motion abnormality (RWMA), no valvular heart disease, (MS/MR), good systolic functions, Inferior Vena Cava (IVC) is dilated, diastolic dysfunction G II "Pseudo normal" appearance [1-5], Stroke variation (SVV) on Left Ventricular Outflow Tract (LVOT) showed fluid responsiveness, passive leg raise (PLR) test supported the same picture.

Re-evaluation showed improving diastolic dysfunction to G I, SVV on LVOT showed positive fluid responsiveness. One litre of CSL was given and discontinued Adrenaline infusion to maintain mean arterial pressure (MAP) of > 65 mmHg.

Noradrenaline was continuously weaned after fluids. Laboratory results came showing Hemoglobin 7.8, INR 1.6, LA 4.3, drain was

### Article Information

**Article Type:** Research

**Article Number:** SJS114

**Received Date:** 17 December, 2018

**Accepted Date:** 25 January, 2019

**Published Date:** 31 January, 2019

**\*Corresponding authors:** Walid S. Alhabashy, Anaesthesia and Critical Care, Temple street Children University Hospital, Mercy University Hospital, Cork, Ireland. Tel: 00353894402228; Email: [wsh2976\(at\)hotmail.com](mailto:wsh2976(at)hotmail.com)

**Citation:** Alhabashy WS, Meeke R (2019) Echocardiography Guided Management of Septic Shock. Scholarly J Surg Vol. 1, Issu: 2 (25-27).

**Copyright:** © 2019 Alhabashy WS. This is an open-access article distributed under the terms of the Creative Commons Attribution License, which permits unrestricted use, distribution, and reproduction in any medium, provided the original author and source are credited.

showing 400 ml of bloody fluid. Fluid responsiveness by Echocardiography was still positive so, one unit of red blood cells (RCC) followed by four units of fresh frozen plasma (FFP) to maintain MAP of 65-70 mmHg.

Noradrenaline is weaned to minimal dose and SVV on LVOT showing no fluid responsiveness, urine output (UOP) increased, LA was 4.3 and acidosis was slowly improving, Bleeding from the drain was decreasing. Vasopressin and Noradrenaline were weaned. All fluids were stopped including RCC and Plasma. Continuous veno-venous hemodialysis (CVVH) was commenced for few hours to help washout of sepsis by-products. maintain MAP of 65-70 mmHg. Patient was reassessed by ECHO before Next step.

After 8 hours of septic shock management patient's acid base status was normalized even after stop of CVVH (4 hours in total). Patient was stable enough to be extubated next day and discharged to the ward after few days in the intensive care unit.

Post extubation Echocardiography was done to evaluate patients baseline ECHO for comparison with his previous Images 1-7, during shock and mechanical ventilation which showed no valvular heart problems or RWMA, normal systolic and diastolic functions, normal cardiac output (COP).

### Discussion

First decision to titrate down Adrenaline and add vasopressin to maintain MAP of > 65 mmHg as tachycardia worsens diastolic dysfunction and more fluids now with increase extravascular lung water (EVLW) and lowers

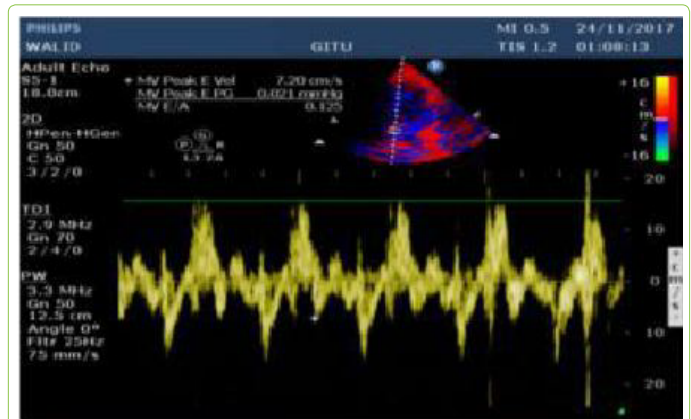


Figure 3: Septal Tissue doppler imaging shows e' is 0.072 m/Sec, E/e' is 11.1 Diastolic dysfunction grade II Pseudo normal.

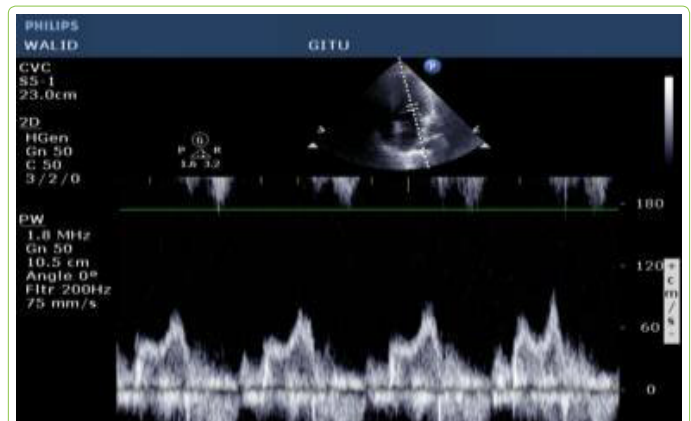


Figure 4: Doppler ultrasound on Mitral inflow shows Diastolic dysfunction grade I immediately after Adrenaline discontinuation.

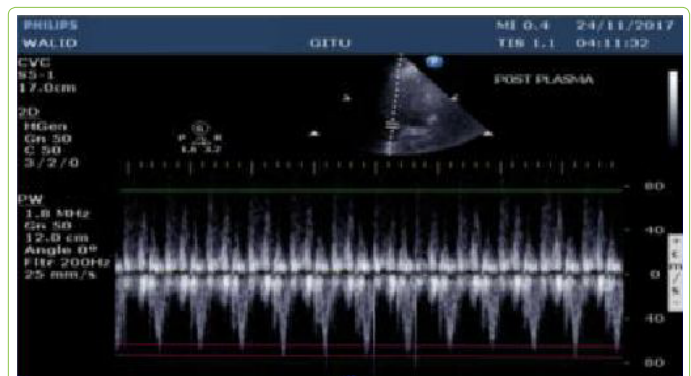


Figure 5: Left ventricular outflow stroke volume variation with respiration indicates no fluid responsiveness.

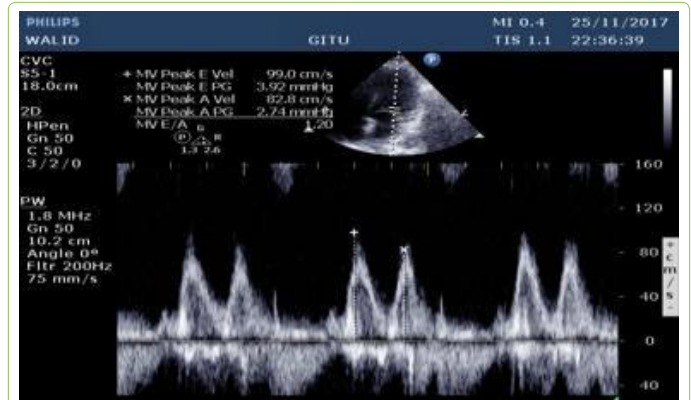


Figure 6: Post extubation and off inotrope/Vasopressor, Doppler ultrasound on Mitral inflow shows normal Diastolic functions E velocity is 0.99 m/Sec.

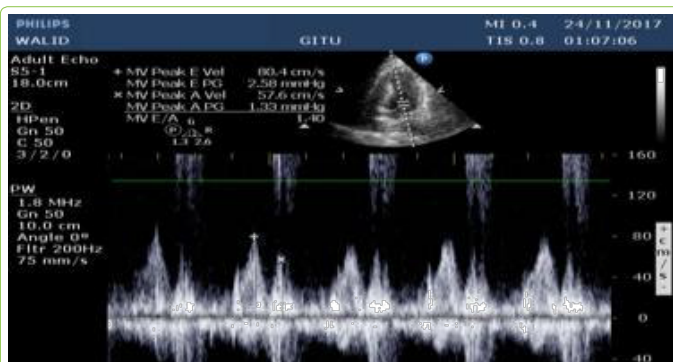


Figure 1: Doppler ultrasound on Mitral inflow shows Diastolic dysfunction grade II Pseudo normal, Peak E velocity is 0.80 m/Sec, E/A ratio is 1.4.

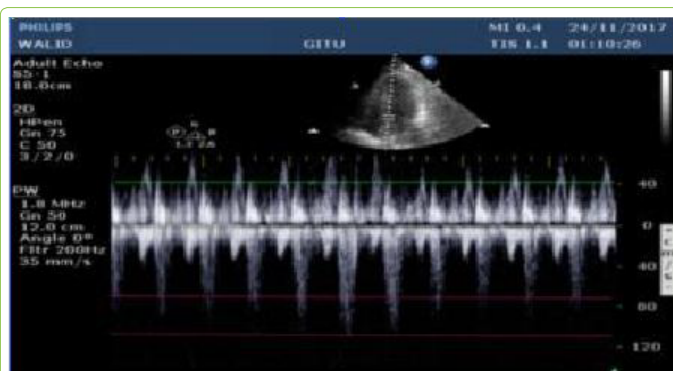
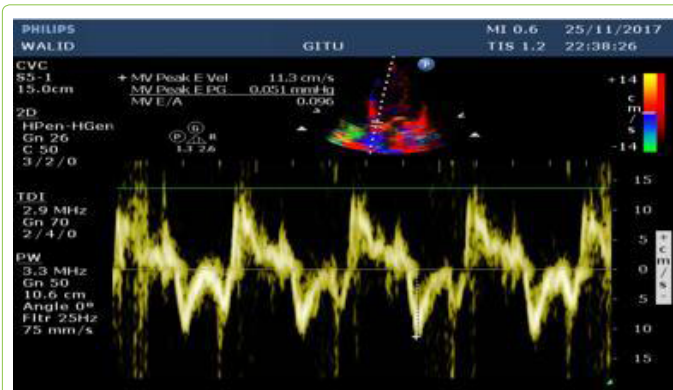


Figure 2: Left ventricular outflow stroke volume variation with respiration indicates fluid responsiveness.



**Figure 7:** Post extubation and off inotrope/Vasopressor, Septal Tissue doppler imaging with septal e' is 0.11 and E/e' is 9.0 shows Normal Diastolic function.

arterial oxygen tension to fraction of inspired Oxygen ( $\text{PaO}_2/\text{FiO}_2$ ) ratio and getting false impression of fluid overload.

Blood and Plasma was given as volume expanders in case of ongoing blood loss and abnormal coagulation profile. Continuous hemodialysis was started early to help washout of sepsis by-products and anion gap acidosis normalization.

## Conclusion

Echocardiography guided resuscitation of septic shock helps to titrate and time fluids, vasopressors and inotropes according to dynamic changes in the cardiovascular system with frequent assessment of systolic and diastolic functions, extravascular lung water and systemic vascular resistance.

## References

1. Via G, Price S, Storti E (2011) Echocardiography in the sepsis syndromes. *Crit Ultrasound J* 3: 71-85.
2. De Geer L, Engvall J, Oscarsson A (2015) Strain echocardiography in septic shock-a comparison with systolic and diastolic function parameters, cardiac biomarkers and outcome. *Critical Care* 19: 122.
3. Cholley BP, Vieillard-Baron A, Mebazaa A (2006) Echocardiography in ICU: time for widespread use. *Intensive Care Med* 32: 9-10.
4. Boyd JH, Walley KR (2009) The role of echocardiography in hemodynamic monitoring. *Curr Opin Crit Care* 15: 239-243.
5. Marik PE (2011) Surviving sepsis: going beyond the guidelines. *Ann Intensive Care* 1: 1-17.