

Surgical Repair of Behçet's Aortic Aneurysms in the Era of Endovascular Surgery

Ahmed Mousa^{1,2*}
Ibrahim Hanbal¹
Alaa Sharabi¹
Ossama M. Zakaria²
Ahmed M. Odeh²
Abdelfattah K. Nassar³
Sami Abdulhakim³

¹Department of Vascular and Endovascular Surgery, Al-Hussain University Hospital, Faculty of Medicine for Males, Al-Azhar University, Cairo, Egypt

²Divisions of Vascular and General Surgery, Department of Surgery, College of Medicine, King Faisal University, Al-Ahsa, Saudi Arabia

³Department of Rheumatology and Rehabilitation, Al-Hussain University Hospital, Faculty of Medicine for Males, Al-Azhar University, Cairo, Egypt

Abstract

Background: We described an operative surgical repair of abdominal aortic aneurysms in patients with Behçet's disease followed by the application of an outer layer of the same used graft material wrapped around the vascular anastomoses in combination with pre- and post-operative immunosuppressive therapy to protect it from postoperative pseudoaneurysm formation.

Methods: We retrospectively evaluated both the open surgical repair of abdominal aortic aneurysms repair and immunosuppressive medication as an adjuvant treatment in patients with Behçet's disease, during the period from January 2010 to December 2013. Patients' data were collected, and clinically evaluated. The imaging investigations, the surgical procedure, graft selection, graft-related complications were analyzed. Operative intervention was performed for symptomatic patients, and patients with expanding aneurysms ≥ 5.5 cm. Those patients who had having Behçet's carotid aneurysms, patients with thoraco-abdominal aortic aneurysms, patients with peripheral arterial aneurysms and those patients with venous system involvement were excluded from the study.

Results: Ten patients included in the study. There were 8 males and 2 females; the male-to-female ratio, (4:1) with the mean age of 34 ± 2 years (range 25-40 years old). Nine out of 10 patients were presented with concomitant infrarenal abdominal aortic aneurysms and bilateral iliac artery aneurysms and the remaining patient presented with an isolated infrarenal abdominal aortic aneurysm. Immunosuppressive therapy was given pre- and post-operatively. Heparin-bonded synthetic Dacron[®] Y-shaped graft was used for patients with concomitant abdominal aortic and iliac aneurysms (n=9) and tube graft was used for the isolated infrarenal abdominal aortic aneurysm (n=1). None of the postoperative complications were observed especially, anastomotic pseudoaneurysm, however, no other graft-related complications were observed after 2 years of follow up.

Conclusion: Surgical repair of abdominal aortic aneurysms in patients with Behçet's disease using the wrapping technique at the site of vascular anastomoses as a prophylactic measure to prevent postoperative pseudoaneurysm formation, in combination with immunosuppressive therapy is feasible, safe and effective technique associated with low morbidity and mortality.

Keywords: Abdominal aortic aneurysm, Behçet's disease, Anastomotic pseudoaneurysm, Heparin-bonded Dacron[®] graft, Prosthetic prophylactic wrapping, Reinforcement of vascular anastomosis.

Article Information

Article Type: Research

Article Number: SJS101

Received Date: 06 January, 2016

Accepted Date: 24 January, 2016

Published Date: 27 February, 2016

***Corresponding author:** Dr. Ahmed Mousa, Assistant Professor of Vascular Surgery, Department of Vascular Surgery, Al-Hussain University Hospital, Faculty of Medicine for Males, Al-Azhar University, Cairo, Egypt. Assistant Professor of Vascular Surgery, Department of Surgery, College of Medicine, King Faisal University, Al-Ahsa, Saudi Arabia. Tel: +20 122 413 7887; +966 559904848 E-mails: isvascular@yahoo.com & asgbi@azhar.edu.eg

Citation: Mousa A, Hanbal I, Sharabi A, Zakaria OM, Odeh AM, et al. (2016) Surgical Repair of Behçet's Aortic Aneurysms in the Era of Endovascular Surgery. Scholarly J Surg. Vol: 1, Issu: 1 (01-07).

Copyright: © 2016 Mousa A, et al. This is an open-access article distributed under the terms of the Creative Commons Attribution License, which permits unrestricted use, distribution, and reproduction in any medium, provided the original author and source are credited.

Introduction

Behçet's disease is a multisystem chronic inflammatory disease characterized by neurologic, cardiovascular, pulmonary, as well as musculoskeletal manifestations. Vascular involvement occurs in about 7% to 29% of affected patients [1]. The vascular disease develops in up to 25% to 35% of the patients and has a definite male predominance. Large artery involvement occurs in 1.5% to 2.2% of all patients with Behçet's disease. Whereas aneurysms are more common than occlusions. The most common sites for aneurysms are the abdominal aorta, pulmonary, femoral, popliteal, and carotid arteries [2]. Large vessel arteritis is uncommon but considered as a major cause of mortality and Behçet's disease-related arterial complications [3], such as anastomotic site pseudoaneurysms and graft occlusion that occurs during the postoperative course [4]. Conventional open surgery is the most commonly used treatment for the arterial lesions in Behçet's disease patients [5]. The vascular anastomosis can be reinforced and wrapped by using prosthetic materials such as polytetrafluoroethylene (PTFE) or Dacron® as a patch graft [6]. The use of a normal arterial segment/the use of an extra-anatomic bypass may be recommended by some surgeons [7]. Recently, the deployment of a covered stent using the endovascular technique seems to be a safe and effective method [8]. In this article, we reported our initial experience on prophylactic prosthetic wrapping of vascular anastomoses for treatment of patients with Behçet's aortic aneurysms in combination with immunosuppressive therapy as an adjunctive treatment to prevent anastomotic site pseudoaneurysm formation.

Patients and Methods

From January 2010 to December 2013, a four-year retrospective study was performed. A data of 10 patients with Behçet's aortic aneurysms were collected from Al-Hussain University Hospital, Faculty of Medicine for Males, Al-Azhar University, Cairo, Egypt. All patients' data were collected to retrieve their demographics and their clinical presentation. In addition to the preoperative investigations, the surgical procedure, the postoperative follow up including postoperative different imaging modalities and the postoperative complications.

Inclusion criteria

All patients with Behçet's aortic aneurysmal disease were diagnosed according to the criteria of the International Study group for Behçet's disease. These criteria include Behçet's disease patients with an oral aphthous ulcer, uveitis, oligoarthritis and vasculitic aortic aneurysm [9]. All treated patients were having a combination of both AAA and iliac artery aneurysms (n=9), except only one case (n=1) who presented with an isolated AAA. All aneurysms were infrarenal and their shapes were saccular except the case who presented with an isolated infrarenal AAA was having a huge fusiform aneurysm measuring more than 10 cm in diameter as diagnosed by computed tomography angiography (CTA). All patients underwent Duplex ultrasonography and CTA scanning (Figure 1). The indications for surgery included AAA with peripheral arterial symptoms e.g. intermittent

claudication pain or abdominal symptoms e.g. pulsatile abdominal mass with or without low back pain. In addition to an expanding aneurysm ≥ 5.5 cm in diameter.

Exclusion criteria

- Behçet's disease patients with;
- peripheral arterial aneurysms,
 - thoraco-abdominal aortic aneurysms,
 - carotid aneurysms
 - venous system involvement.

Operative repair

The used graft for aneurysm repair was heparin-bonded Dacron® graft, which is made of polyethylene terephthalate (PET) (Dacron®) - heparin-impregnated Dacron® graft [InterGard heparin-bonded Dacron® grafts (MAQUET Holding GmbH & Co. KG., Rastatt, Germany)]. We used Y-shaped graft, the size of which ranged from (16mm×8mm) to (18mm×9mm) and only one tube graft and its size was (20mm) in diameter. The open surgical technique was performed through a transperitoneal approach. The infrarenal abdominal aorta was exposed showing the aneurysm sac (Figure 2), followed by exposure of the iliac arteries. Two separate longitudinal incisions were performed at both groins centered at the mid-femoral point to expose the common femoral artery on both sides for distal graft anastomoses. Systemic heparinization was given in a dosage of (75-100 U/kg) and the aortic neck proximal to the aneurysm sac was clamped followed by clamping of the iliac arteries. The aneurysm sac was opened longitudinally and end-to-end vascular anastomosis was performed at the aorta distal to the origin of the renal arteries using a

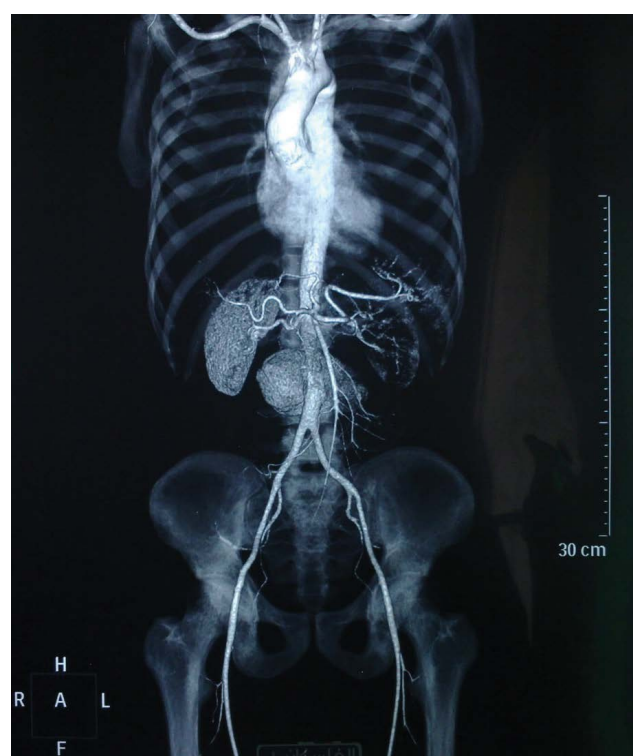

Figure 1: CTA showing infrarenal abdominal aortic aneurysm.

running 4/0 Prolene suture. The distal anastomoses were performed to the common femoral artery on both sides in cases of aortobifemoral bypass surgery, while in cases of an isolated infrarenal AAA the distal end of the tube graft was anastomosed to the distal part of the abdominal aorta proximal to its bifurcation. The proximal and distal anastomoses were reinforced by wrapping with a synthetic patch graft (Figures 3-5) from the same used graft material in a single or double layer technique.

Medical management

Immunosuppressive therapy was given before and after the aneurysm repair. Prednisolone was given in a dose of (5-60 mg/day), according to each patient's clinical condition, and azathioprine (50-100 mg/day) and/or colchicine in a dose of (1.2 mg/day), were added if needed according to clinical condition and disease activity. The dose of immunosuppressive agents was adjusted according to the level of erythrocyte sedimentation rate (reference range <20 mm/h) [1]. Follow up was performed every one month up to 24 months with the mean follow up period of 12.11 ± 8.03 month (rang: 1-24 month).

Results

This study included a total number of 10 patients. They were 8 (80%) males and 2 (20%) females with the male to female ratio 4:1. Patients' mean age 34 ± 2 years (range: 25-40). Their clinical presentations vary from asymptomatic aneurysms in 5 patients (50%), pulsatile abdominal mass in 2 cases (20%), and the remaining 3 patients (30%) presented

with a variety of clinical symptoms and signs including a painful abdominal mass with back pain, intermittent claudication pain (table1). Out of 10; 9 cases were presented with a combination of infrarenal AAA and bilateral common iliac artery aneurysms and the remaining case was presented with an isolated infrarenal AAA. Nine aneurysms were saccular in shape and the remaining one was fusiform. The mean aneurysm diameter 5.48 ± 1.90 cm (range: 4.20-10.8 cm). Duplex B-Mode ultrasonography and CTA scanning were performed for all patients. All patients had received medical therapy pre and postoperatively in the form of corticosteroid as the first line treatment for their original Behçet's disease to control the major vascular involvement in combination with azathioprine or cyclophosphamide. All patients underwent an elective surgical repair. The operative technical success was accomplished in 100% of cases. There were no intraoperative complications. The adopted surgical technique favored the use of a synthetic heparin-bonded Dacron® bifurcated Y-shaped and tube grafts. The repair was done in a healthy arterial segment and the proximal and distal anastomoses were wrapped and reinforced by either single or double layer of a synthetic patch graft similar to the used graft for aneurysm repair. Postoperative complications such as anastomotic pseudoaneurysms, arterial rupture, graft infection, and thrombosis does not developed during the follow-up period (i.e. 24 months). Systemic immunosuppressive therapy was given postoperatively to all patients in the form of azathioprine, together with methyl prednisolone/colchicine if needed. Thereafter, oral immunosuppressive therapy was continued for two years

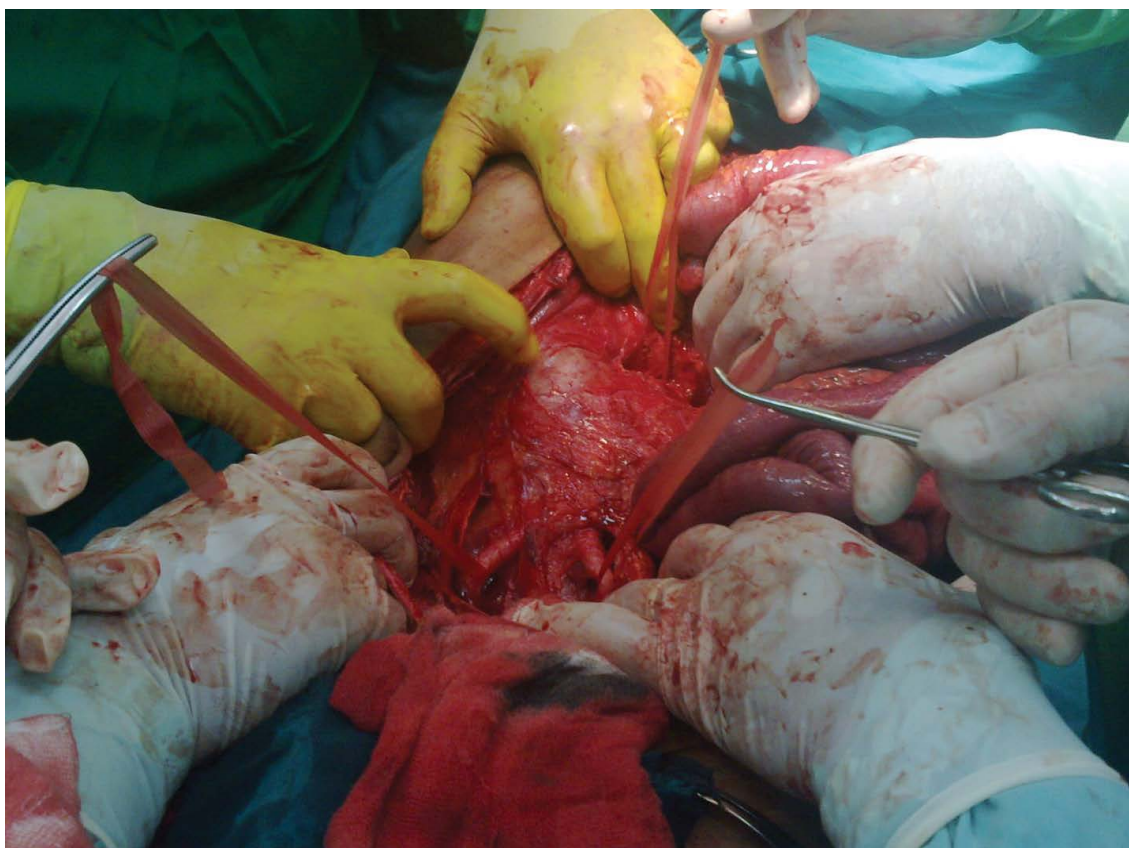


Figure 2: Transperitoneal operative exposure of an infrarenal abdominal aortic aneurysm.

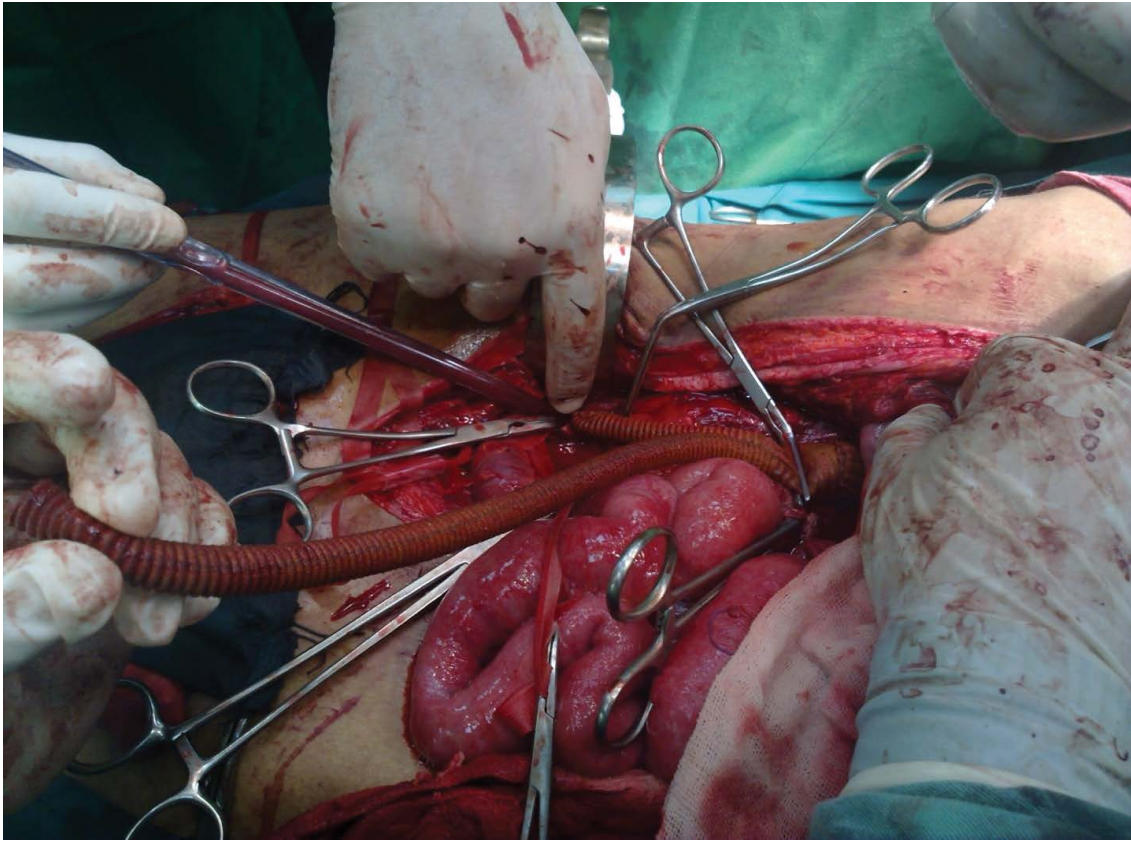


Figure 3: Prosthetic wrapping and reinforcement of the proximal infrarenal aortic anastomosis with a patch of a synthetic heparin-bonded Dacron® graft.

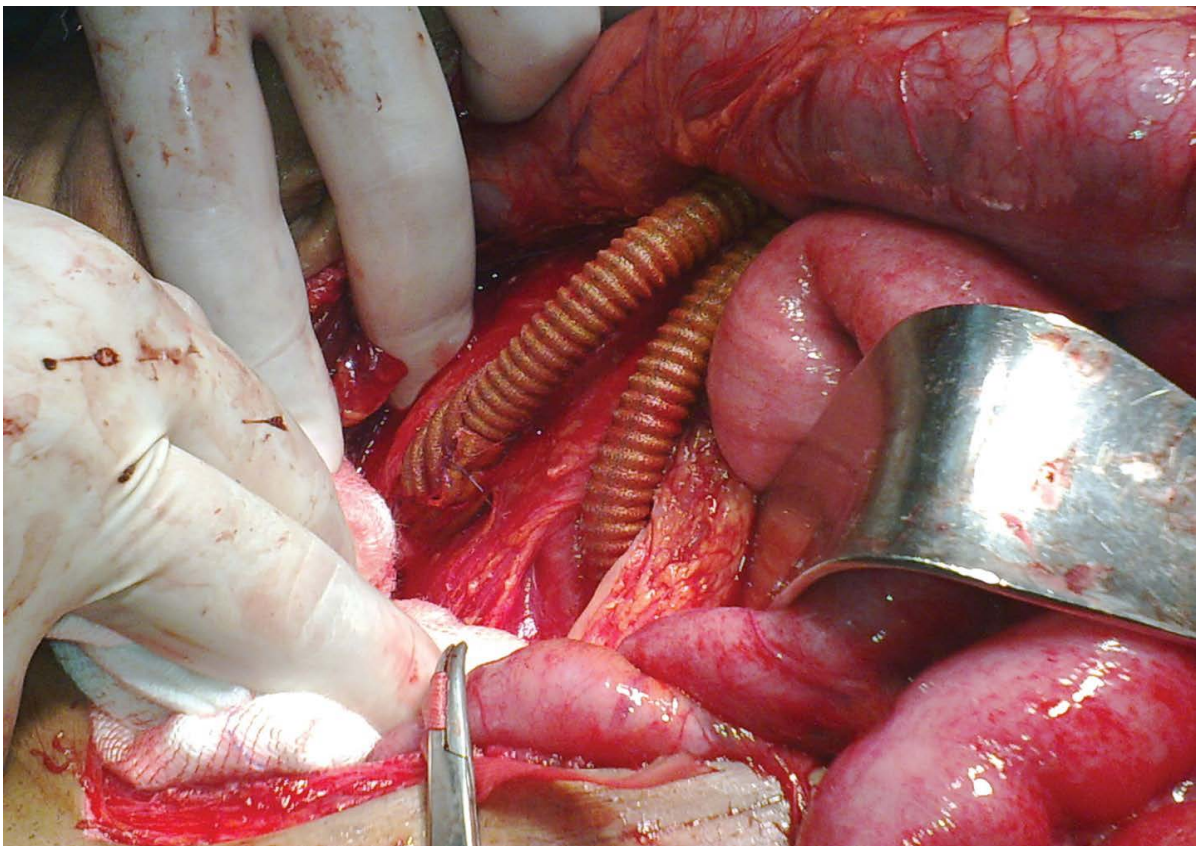


Figure 4: Prosthetic reinforcement and wrapping of the distal right aortofemoral anastomosis with a patch of a synthetic heparin-bonded Dacron® graft in cases of aortobifemoral bypass surgery.

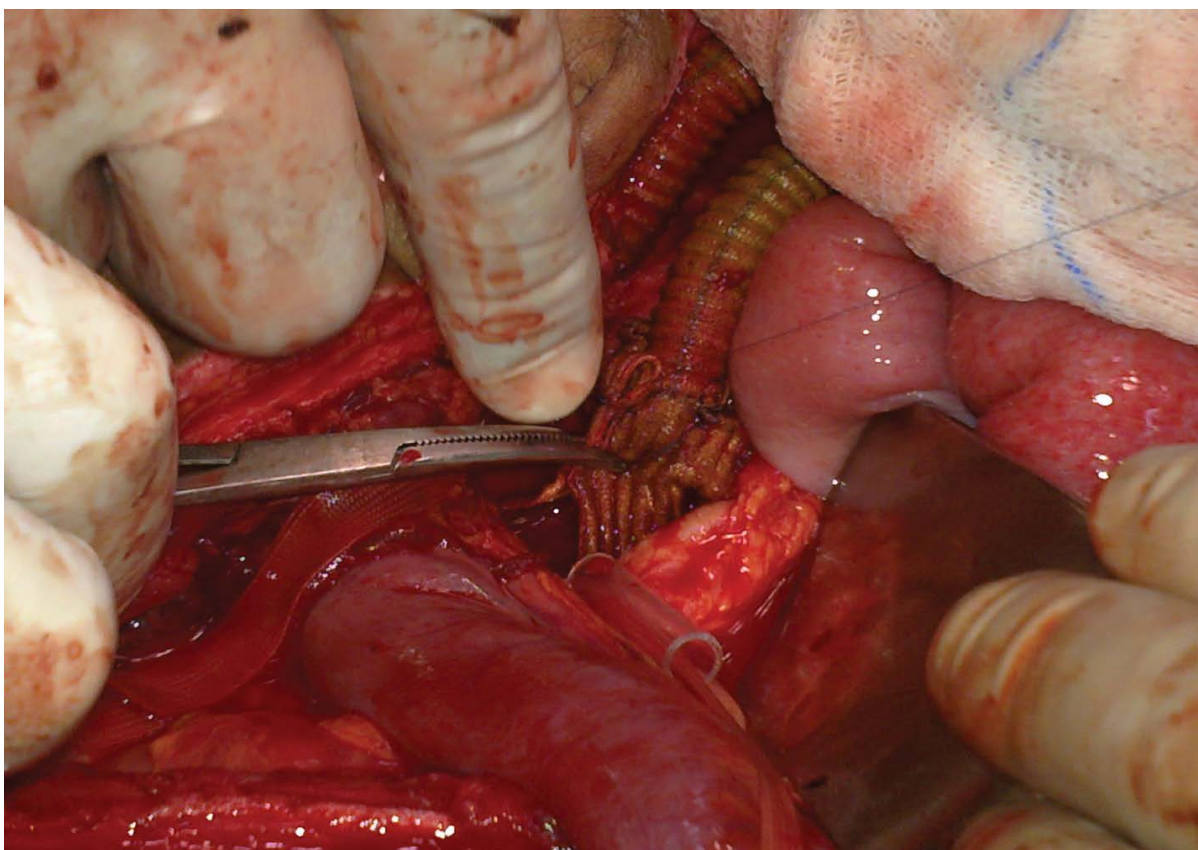


Figure 5: Prosthetic reinforcement and wrapping of the distal left aortofemoral anastomosis with a patch of a synthetic heparin-bonded Dacron® graft in cases of aortobifemoral bypass surgery.

and controlled with the aid of the rheumatologists from the same institution.

Discussion

Behçet's disease is commonly associated with vascular complications in the form of peripheral arterial aneurysms that mostly affect all arteries [10]. The most common site of aneurysm formation is the aorta, followed by the pulmonary and femoral arteries [11-13]. It is commonly pronounced in almost all major arteries and the abdominal aorta is the most commonly involved artery. Rupture is the most common complication and the most common cause of vascular-related death in this disease [14-17]. On the other hand, multiple aneurysms are relatively common [18-20]. In this study, we reported our local experience in treatment of patients with Behçet's aortic aneurysms. We reported a marked male predominance with a male to female ratio of 4:1 this is coinciding with previously published data [20-23]. The comparison of our collected data to some of those in the literature was listed in (table 2). The commonest sites of aneurysms were the infrarenal abdominal aorta. These data are similar to the previously published one [13]. Diagnostic investigations were performed for all of our patients included B-Mode sonographic assessment and CTA, which are similar to that described in the literature [8]. In our series 9 out of 10 patients were presented with a concomitant abdominal and iliac artery aneurysms and one patient presented with an isolated AAA. Five of them were

asymptomatic coinciding with a previously published data [24]. In some reported data [12] the patient's age incidence was young that goes in accordance with our series where the mean age was 34 ± 2 . Aneurysms in patients with Behçet's disease is the most complicated and challenging pathology to face the vascular surgeon due to technical difficulties and frequent postoperative complications [20-21], and the experiences with the endovascular treatment is still limited [22]. Some authors supported a surgical approach with simple arterial ligation to avoid reconstructive complications in peripheral arterial lesions [13]. To prevent anastomotic pseudoaneurysms, prosthetic wrapping to the proximal and distal anastomotic sites in every case of graft interposition was done using a patch of heparin-coated Dacron® graft (i.e. the same used graft for aneurysm repair) contradicting that reported in the literature using omental wrapping technique [13]. Others reported that they replaced the infrarenal AAA with a knitted Dacron® bifurcated graft and the proximal and distal anastomotic sites were reinforced and wrapped with a none-absorbable mesh wrapping technique [25]. However, in our series, we have performed the same technique using the knitted heparin-bonded Dacron® bifurcated and tube grafts in the repair of the infrarenal AAA and the proximal and distal anastomotic sites were reinforced with a patch of a heparin-bonded Dacron® graft. Systemic immunosuppressive therapy was given to all patients pre and postoperatively with the medicine dosage and combination individually tailored like what was previously described [12, 19, 20]. The postoperative course is often complicated by

Table 1: Clinical presentation of patients with Behçet AAA.

	No.	%
Asymptomatic	5	50
Pulsatile abdominal mass	2	20
Painful abdominal mass with back pain	2	20
Intermittent claudication	1	10

Table 2: Our analysis of results in relation to that reported in some literature.

	Current Study	Kalko <i>et al.</i> [7]	Koksoy <i>et al.</i> [10]	Tuzun <i>et al.</i> [15]	Iscan <i>et al.</i> [22]
Number of patients	10	12	23	15	5
Peripheral aneurysms operated on	10	12	29	18	6
Anastomotic pseudoaneurysm	0	2	7	4	N/A
Graft occlusion	0	1	11	4	1
Amputation	0	N/A	5	0	1
Related mortality	0	0	6	2	0
Follow-up (months)	12.11	17	83.9	54.4	24.4

N/A: Not available.

anastomotic site pseudoaneurysms, graft occlusions and recurrent aneurysms, leading to a relatively high mortality rate [11]. We used bifurcated graft for treatment of patients with both aortic and iliac aneurysms (i.e. aortobifemoral bypass technique) and a tube graft for isolated AAA with wrapping and reinforcement of the proximal and distal anastomotic sites with patch graft as a single or double layered from the same used graft material (i.e. heparin-bonded Dacron® graft) to prevent pseudoaneurysm formation. No postoperative complications were reported in our series, which are resembling previously published data [26]. These good results may be due to the technique that we have adopted by using the reinforcement and wrapping at the anastomotic site. In addition to the administration of pre and postoperative immunosuppressive therapy. So, early diagnosis and early administration of immunosuppressive therapy will be helpful in preventing the formation and progression of this life-threatening complication of Behçet's disease [27]. We discussed a relatively old surgical technique in the endovascular era aiming to explore its success and safety in treating arterial aneurysms in Behçet's disease patients. However, a further study with a long-term follow-up is necessary to evaluate the efficacy and safety of this technique.

Conclusion

Surgical treatment of patients with Behçet's aortic aneurysms using prosthetic wrapping technique at the site of surgical anastomoses as a prophylactic measure to prevent post-surgical complications especially pseudoaneurysm formation, in combination with immunosuppressive therapy to prevent Behçet's disease activation is feasible, safe and effective technique associated with low morbidity and mortality. In addition, it is associated with better postoperative results and lower recurrence rates than endovascular procedure, especially in a low resource-challenged setting as in our cases. Increasing number of similar cases with long-term follow up may give more realistic information concerning this pathology. This will be

discussed later in our coming research.

Conflict of interest

No conflict of interest

Declaration of interest

We declare no competing interests.

References

- Kim SW, Lee DY, Kim MD, Won JY, Park SI, et al. (2014) Outcomes of endovascular treatment for aortic pseudoaneurysm in Behçet's disease. *J Vasc Surg* 59: 608-614.
- Tuzun H, Seyahi E, Arsian C, Hamuryudan V, Besirli K, et al. (2012) Management and prognosis of nonpulmonary large arterial disease in patients with Behçet disease. *J Vasc Surg* 55: 64-67.
- Cho SB, Kim T, Cho S, Shim WH, Yang MS, Bang D (2011) Major Arterial Aneurysms and Pseudoaneurysms in Behçet's Disease: Results from a Single Centre. *Scand J Rheumatol* 40(1): 1219-1219.
- Hosaka A, Miyata T, Shigematsu H, Shigematsu K, Okamoto H, et al. (2005) Long-term outcome after surgical treatment of arterial lesions in Behçet's disease. *J Vasc Surg* 42: 116-121.
- Balcioğlu O, Ertugay S, Bozkaya H, Parildar M, Posacioglu H (2015) Endovascular Repair and Adjunctive Immunosuppressive Therapy of Aortic Involvement in Behçet's Disease. *Eur J Vasc Endovasc Surg* 50: 593-598.
- Honjo O, Yonuki K, Shichijo T, Oba O (2006) Peripheral pseudoaneurysm in active Behçet's disease: Surgical and perioperative therapeutic strategies. *Ann Vasc Surg* 20: 664-668.
- Kalko Y, Basaran M, Aydin U, Kafa U, Basaranoglu G, Yasar T (2005) The surgical treatment of arterial aneurysms in Behçet's disease: A report of 16 patients. *J Vasc Surg* 42: 673-677.
- Liu CW, Ye W, Liu B, Zeng R, Wu W, et al. (2009) Endovascular treatment of aortic pseudoaneurysm in Behçet disease. *J Vasc Surg* 50: 1025-1030.
- International Study Group for Behçet's Disease (1999) Criteria for diagnosis of Behçet's disease. *Lancet* 335: 1078-1080.
- Koksoy C, Gyedu A, Alacayir I, Bengisun U, Uncu H, Anadol E (2011) Surgical treatment of peripheral aneurysms in patients with Behçet's disease. *Eur J Vasc Endovasc Surg* 42: 525-530.
- Safar HA, Abou-Khamseen S, Kansou J, Abubacker S, Francis I, et al. (2005) Vascular aneurysms in Behçet's Disease. *Surgical Practice* 9:35-40.
- Park JH, Han MC, and Bettmann MA (1984) Arterial manifestations of

- Behçet disease. *AJR Am J Roentgenol* 143: 821-825.
13. Le ThiHuong D, Wechsler B, Papo T, Piette JC, Bletry O, Vitoux JM, et al. (1995) Arterial lesions in Behçet's disease. A study in 25 patients. *J Rheumatol* 22: 2103-2113.
14. Kwon TW, Park SJ, Kim HK, Yoon HK, Kim GE, Yu B (2008) Surgical treatment result of abdominal aortic aneurysm in Behçet's disease. *Eur J Vasc Endovasc Surg* 35: 137-180.
15. Tüzün H, Beşirli K, Sayin A, Vural FS, Hamuryudan V, Hizli N, et al. (1997) Management of aneurysms in Behçet's syndrome: an analysis of 24 patients. *Surgery* 121: 150-156.
16. Hamza M (1987) Large artery involvement in Behçet's disease. *J Rheumatol* 14: 554-559.
17. Gurler A, Boyvat A, Tursen U (1997) Clinical manifestations of Behçet's disease: an analysis of 2147 patient. *Yonsei Med J* 38: 423-427.
18. Okita Y, Ando M, Minatoya K, Kitamura S, Matsuo H (1998) Multiple pseudoaneurysms of the aortic arch, right subclavian artery, and abdominal aorta in a patient with Behçet's disease. *J Vasc Surg* 28: 723-726.
19. Yamana K, Kosuga K, Kinoshita H, Uruguchi K, Kinoshita T, Hirata Y, et al. (1988) Vasculo-Behçet's disease: immunological study of the formation of aneurysm. *J Cardiovasc Surg (Torino)* 29: 751-755.
20. Bartlett ST, McCarthy WJ, Palmer AS, Funn WR, Bergan JJ, Yao JST (1988) Multiple aneurysms in Behçet's disease. *Arch Surg* 123: 1004-1008.
21. Park JH, Chung JW, Joh JH, Song SY, Sang JS, Chung KS, et al. (2001) Aortic and arterial aneurysms in Behçet disease: management with Stent-Grafts: initial experience. *Radiology* 220: 745-750.
22. Iscan ZH, Vural KM, and Bayazit M (2005) Compelling nature of arterial manifestations in Behçet disease. *J Vasc Surg* 41: 53-58.
23. Alejandro RM, Ana HC, Carlos dela CC, Suzana GR, Rafael GM (2012) Atypical vascular involvement in a case of Behçet's disease. Hindawi Publishing Corporation, Case Report in Surgery Article ID 848101, 5 pages.
24. Okada K, Eishi K, Takamoto S, Ando M, Kosakai Y, Nakano K, et al. (1997) Surgical management of Behçet's aortitis: a report of eight patients. *Ann Thorac Surg* 64: 116-119.
25. Inada H, Katsumura T (2000) Behçet's Disease. *Textbook of Angiology*, Ch.78: 963-970.
26. Ohira S, Watanabe T, Yaku H (2015) Layered wrapping technique combined with oxidized cellulose and vascular prosthesis for effective haemostasis in aortic surgery. *Interactive CardioVascular and Thoracic Surgery* 20: 276-277.
27. Jayachandran NV, Rajasekhar L, Chandrasekhara PK, Kanchinadham S, Narsimulu G (2008) Multiple peripheral arterial and aortic aneurysms in Behçet's syndrome: a case report. *Clin Rheumatol* 27: 265-267.