

Review of Thiamin Therapy in Space Occupying Lesions: Preliminary Approach of Physiologic Therapy of Tumors

Benjamin Y Lee^{1,3*}
Julia H Bai²
LI Zhengya³
WANG Yanrong³

¹Author's mailing address: 21330 Branford Hills Lane, Katy, TX, 77450, USA

²Master Program Student, Department of Epidemiology, Texas A&M University, Institute address: 400 Bizzell St. College Station, TX, 77843, USA

³Medical volunteer, LI Zhengya & WANG Yanrong assistants of Uncle Ben's Clinic Service address: Uncle Ben's Clinic at Xiaoshawo village in the west suburban area of Tianjin City, 300380, China.

Abstract

This review describes 4 kinds of tumors diagnosed within a year, 1959, in a very small and primitive medical service of a concentration camp in China. Because all laborers suffered from prolonged terribly hard labor with hunger, queer, or unique severe diseases of many kinds involving different systems were commonly found. For example, submandibular gland cyst, Baker's cyst, lipoma, and osteosarcoma were encountered within that year. Kidney cysts recently found in a village were also added. As a whole, their therapeutic response to parenteral thiamin was either dramatic or drastic, making surgical removal not necessary. However, it couldn't be published due to multiple social factors in the past.

Keywords: Baker's cyst, Beriberi Cyst, Kidney cyst, Lipoma Osteosarcoma Submandibular gland cyst, Thiamin deficiency.

Thiamin injections were used in the therapy of space occupying lesions as early as 1959 in a concentration camp [1]. Since all laborers suffered from prolonged extremely hard labor with hunger, very queer or unique severe diseases of different kinds and involving multiple systems were commonly found. For example, four kinds of tumors were accidentally encountered and confirmed within a year from a very small and primitive medical service, including submandibular gland cyst, Baker's cyst, lipoma and osteosarcoma. Although their pathology was quite different, however, their therapeutic response to minimal amount of thiamin injections was either dramatic or drastic. It is worthwhile to report albeit they had been discontinued for 60 year due to opposite social factors. In the following, thiamin therapy of cases with submandibular gland cyst, Baker's cyst, lipoma, osteosarcoma are described. Kidney cyst recently found from a village in China was also added.

Case Descriptions

I. Submandibular gland cyst:

A 52 years old beriberi patient developed a cyst for 15 months in his right submandibular region while beriberi status progressed. Since the cyst became larger or smaller as his palpitation, breath shortness and leg edema became advanced or improved for many times, it became a blinking sign of indicating that thiamin deficiency might be the etiology of the cyst and thereby therapy. An intramuscular thiamin HCl 75 mg was then tried. His beriberi status improved and the cyst shrank from 10 X 8 to 10 X 6 cm at the day of injection. This phenomenon was interested by the medical officer who took the following 2 pictures from July and August 1959 as an item for celebrating the coming 10th national day, October 1, the day of liberation of the mainland.

Article Information

Article Type: Research

Article Number: SJASR211

Received Date: 26 December, 2018

Accepted Date: 27 January, 2019

Published Date: 31 January, 2019

***Corresponding author:** Dr. Benjamin Y Lee, Retiree, Biochemical Genetics/Pediatrics Louisiana State University Health Sciences Center in Shreveport Institute Address: 1501 Kings Hwy, Shreveport, LA 71130, USA. Tel: +318-675-5000; Email: benjaminlee30@outlook.com

Citation: Lee BY, Bai JH, Zhengya LI, Yanrong W (2019) Review of Thiamin Therapy in Space Occupying Lesions: Preliminary Approach of Physiologic Therapy of Tumors. Sch J Appl Sci Res Vol: 2, Issu: 1 (29-34).

Copyright: © 2019 Lee BY. This is an open-access article distributed under the terms of the Creative Commons Attribution License, which permits unrestricted use, distribution, and reproduction in any medium, provided the original author and source are credited.

Intra-cystic injections of thiamin 100 mg once a day at the first few days and then only 25-50 mg daily were injected. Cyst content was collected only 3 ml for diagnosis. Immediately after the first intra-cyst injection, patient felt something whirling inside the cyst and also tasted thiamin in his mouth. This meant that his salivary duct was patent. Surprisingly, shortly after each of the first 2 intra-cyst injections, the cyst of 6 X 8 cm disappeared completely but transiently for 1-2 hours and then returned with smaller size. When the cyst reached the size of a walnut, its response to intra-cyst thiamin became sluggish but finally it was eradicated without recurrence.

The second case was a 35 years old male, his cyst of 5 X 7 cm in size reduced gradually without transient disappearance at the initial injections. After intra-cyst thiamin 50 mg injections of 9 times, the smaller cyst disappeared¹.

Baker's cyst

Same etiologic consideration and therapy were then applied in a case of 42 years old with a fresh Baker's cyst which was found only a few days during the exacerbation of his leg pain. The cyst disappeared after 3 intra-cystic injections of thiamin HCl of 50 mg in a week without recurrence. Further cases were observed from a community clinic in Beijing city 1963-1966. All were civil heavy physical laborers such as coal deliverymen, road repairmen, textile workers or construction workers. In civilian cases, the response was not so dramatic because of their better nutrition and easier physical labor. Thiamin 100 mg was injected directly into the cyst once a day. Twelve out of 14 civilian cases were cured. It required 10-15 days in the heavy workers, while others with regular physical activity needed 20-25 injections. Two kindergarten teachers failed, perhaps, high dose of thiamin should be injected.

In each case, a little of cyst fluid content was withdrawn for diagnosis. The content of the first case from the labor camp was very sticky and scant because it was found within a few days after its formation. When dropped the content into alcohol it became white colored gel. The contents of all the civil cases were straw colored liquid like serum except for a female with old clot requiring withdrawal for 3 times.

Baker's cyst of 10 years with 8 X 6 cm and very high in size was found in a female of 58 years old in Tianjin west, Oct 20, 2016 (Figure 1,2). She suffered from general weakness, lassitude, pain in lumbar, leg and knee joints for 10 years with a mass growing in the fossa behind her left knee joint. The wall of the huge cyst was very thick and firm. It resisted her from squatting, otherwise, she would be stumble over. Thiamin 300 mg plus an ampule of VB Co. twice a day and occasionally 200 mg plus VB Co. trice a day were injected into the cyst at the beginning. The cyst content had never been withdrawn. It became soft and decreased in size and height dramatically following each injection. After the 20th injection, its shrinkage became slow. It disappeared after totally 30 injections and the accompanied weakness and all pain were also cured.

Kidney Cysts

Doppler, ultrasonic and CT examinations were commonly used in the hospitals near our tele-clinic and cysts inside human body were often found from our patients. Two cases with kidney cyst were met. One was Ms. GAO TX. Her right kidney was removed October 2012 by the Tianjin Oncology Hospital (case # 342705) due to renal cancer. Follow-up study every 3-5 months revealed a normal left kidney. However, a cyst of 1.5 cm in diameter was found in the left kidney at her third checkup. She accepted physiologic therapy of parenteral thiamin 200 mg plus one ampule of VB Co. twice daily or intermittently with an intention to recover health and eradicate the kidney cyst. After totally injected for 310 times within several months, her ultrasonic study at Jun 29, 2015, revealed disappearance of the cyst. And the majority of her gray hair also turned into black.

Another case was Mr. ZHANG CB, a patient with coronary heart disease.

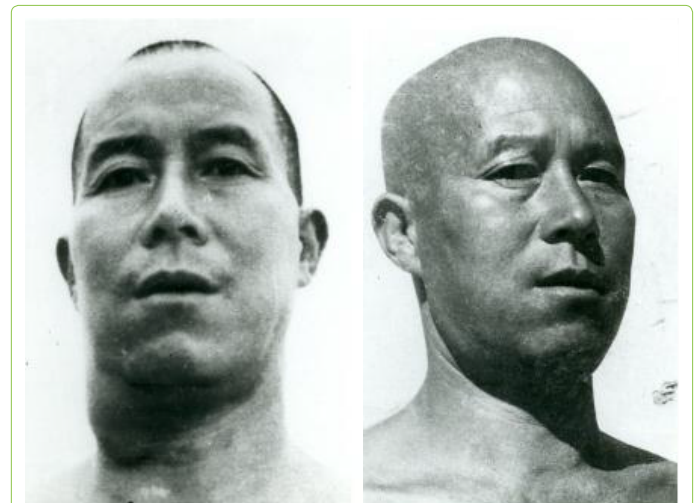


Figure 1: Submandibular gland cyst. The cyst reduced from 6 X 10 to 6 X 8 cm in the left picture. Cyst disappeared after a month in the right.

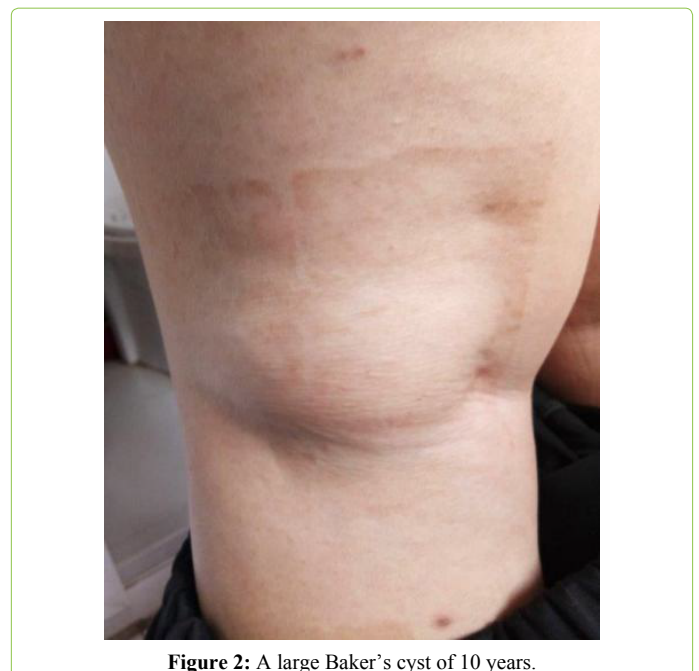


Figure 2: A large Baker's cyst of 10 years.

A cyst of 1.2 X 1.2 cm was found at the left kidney in his public health profiling on Nov 1, 2013 (public profiling # 20131101363Z, p.3). It became 1.3 X 1.9 cm on Oct 30, 2015 (p.2, XQN20151030303Z). He accepted to treat his coronary heart disease from Sep 27, 2016. Within 40 days of parenteral thiamin 300 mg twice daily for his coronary heart disease, kidney cyst disappeared on Nov 6, 2016 (#XQN20161106037Z, p.2), and no recurrence thereafter.

Acute formation of lipoma

A subcutaneous fatty pad usually develops on the shoulder of a professional shoulder pole user. Its size varies from just palpable to a remarkable flatten dome. In a summer day 1959, a slavery laborer found his right shoulder became greatly "grow upward" and sore within 2 days after arduous labor of carrying mud earth when working on canal. Physical examination revealed a soft dome occupying over that shoulder with a height about 5 cm like a hamburger. It was soft with the character of a fatty mass, slightly congestive but tender less. The dome was so high and round unable to carry a pole. Thiamin 50 mg was injected into the round dome. The next day it decreased drastically in size over half and returned to its previous palpable size after the next day. This became the clinical clue for thiamin therapy of a lipoma.

In that winter of 1959, a patient, 54, was diagnosed with a lipoma of 7 X 5 cm at the back of the neck. Aspiration smear revealed fatty droplets. Thiamin HCl 50 mg was injected into the mass for 3 times in a week. Therapeutic effect was confirmed by the flattening of the convex surface although the size unchanged. Further observation was interrupted because the patient died in an accident. While collecting water, he slipped into an ice-surrounded, deep well.

Another case was a 45 years old peasant in Tianjin west. He had 21 fatty lumps of 0.5-5.0 cm for 20 years. Several large lumps (3-5 cm) were located in the arms and forearms while numerous small ones (0.5-1.0 cm) distributed in the back. Thiamin 100 mg was injected once a day into the largest one (5 cm) on the right arm as shown in the figure 3. Its surface became flattened and slightly shank after the first injection and disappeared after 6 injections. Since local injection caused pain and there were a lot of smaller ones to be injected, he decided to stop injections and to wait oral benfotiamine.

Osteolytic osteosarcoma

The real cancer was observed in a 40 years old housewife with prolonged severe malnutrition in the camp. When rising from squatting position to hang clothes for drying she fainted on the ground and her right arm broken. The fracture wound did not heal but swelled progressively and became stony hard and painful disturbing her sleep day and night. Its circumference reached 30 cm at the third month after injury. X-ray film demonstrated a large radiolucent and slightly milky mass with destructive bony lesions and minimal healed osteoid tissues. Dr. Karl Chen, my teacher of orthopedics also inside the camp, diagnosed as osteosarcoma and suggested to have biopsy. The specimen was gritty and non-elastic. The authentic pathology diagnosis by Dr. XIA Renyi of the Peking Union Medical College Hospital in Beijing

was "osteal malignancy" without further classification. Owing to the very rapid course and minimal healing osteoid tissue, it should be osteosarcoma or osteolytic osteosarcoma, the most malignant bone cancer. Thiamin HCl 300 mg was subcutaneously infused around and immediately close to the mass promptly after biopsy. Her general status greatly improved and became pain free for a few days. The circumference of the sarcoma drastically shrank from 30 to 20 cm within two days and the thin and shining local skin became greatly wrinkled. Fifty one percent of cross section area of the mass had been reduced after thiamin as calculated according to circumflex law. When counted the reasonable decrease of its length, the reduction of the cancer volume should be 50-70% or more of the original. Thiamin therapy was extremely successful, however, no way to have more thiamin. She died 2 weeks later due to poor social factors and the circumference of her osteosarcoma returned to 22 cm. It is worthwhile to take her as an important example for further clinical study by multiple institutes.

Discussion

Theoretical basis of thiamin therapy:

Thiamin therapy was based on clinical observation in a labor camp 1958-1962 before and during nationwide hunger when current biochemical theories were unavailable. Actually, in the first case with "blinking" parallelism of beriberi advancement and cyst enlargement became the teller of the etiology and therapy of the cyst. Thiamin therapy was thereby tried one after another. Therapeutic effect were dramatically successful in all of the four items, submandibular gland cyst, Baker's cyst, lipoma, and osteosarcoma.

Role of thiamin in cancer formation: oncogenic or oncotherapeutic:

Excessive thiamin has been considered as oncogenic. Cascante et al [2] claimed that thiamin supported a high rate of nucleic acid ribose synthesis for tumor cell survival,

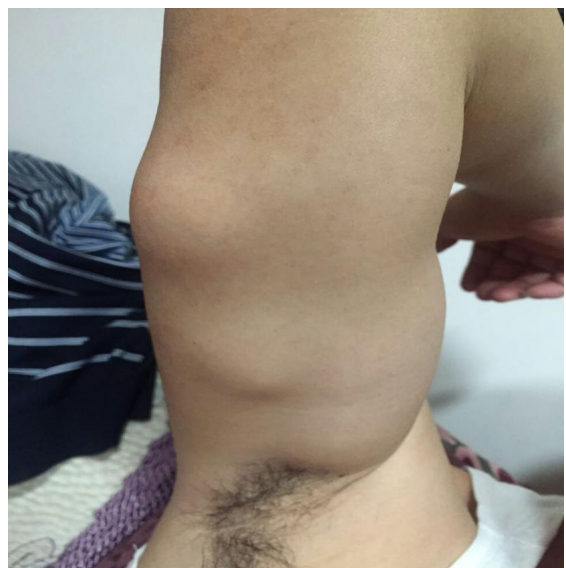


Figure 3: The upper large lipoma (5 cm) was eradicated after 6 injections of thiamin 100 mg.

proliferation, and chemotherapy resistance. Furthermore, Boros et al [3] also implied that excess thiamin was a cancer promoter and suggested development of anti-thiamin therapy. It is just exactly and absolutely total opposite to our clinical practice [4].

Parenteral thiamin of large dose had been confirmed to be cancer therapeutic in recent years by Zastre [5], Hanberry [6], Sweet [7], Luong KV and Nguyen LT [8]. They demonstrated that high-dose thiamin decreased proliferation in a mechanism similar to that of dichloracetate (a new anti-cancer medicine) in SK-N-BE and Panc-1 cells (neuroblastoma and pancreas cancer cell lines). Both thiamin and dichloracetate have the following functions:

- A. Reducing: 1. pyruvate dehydrogenase phosphorylation, 2. mitochondrial membrane potential, 3. glucose consumption and lactic acid production, 4. reactive oxygen species production.
- B. Inducing: caspase-3 mediated apoptosis, cancer cell natural death.

These findings described a potential mechanism by which high-dose thiamin reduced *in vivo* tumor growth. Treatment regimens with high-dose thiamin may be a safer more tolerated alternative to dichloracetate supplementation. Future work will be needed to establish the role of thiamine homeostasis genes in the dose-response and if any non-cofactor roles of thiamin may contribute to the mechanism of toxicity. These become the second solid basis of thiamin therapy for this author.

Thiamin was proved a cancer protector in dietary study

The following dietary case-control reports supported that VB1 is beneficial in preventing cancer:

In a study of 1,207 colorectal cancer cases and 3,521 controls, Tuynes [9] found that thiamin was associated with a relative risk reduction of 0.62 (95% confidence interval 0.50-0.78) for colon cancer and 0.73 (95% confidence interval 0.57-0.94) for rectum cancer.

Slattery et al [10] studied 1,993 colon cancer cases and 2,410 controls and found that colon cancer risk was inversely associated with the intake of vegetables, whole grains, and some vitamins including thiamin, pyridoxine, and niacin.

In a study of 180 cases of colorectal cancer and 180 controls of the same sex and age range, a consistent inverse association between cancer occurrence and the intake of retinol, thiamin, carotene, vitamin C and vitamin E was confirmed by Jedrychowski et al [11].

Du et al [12] found evidence that thiamin prevented prostate cancer in 102 case-control pairs. The multivariate adjusted odds ratio was 0.029 (95% confidence interval 0.009-0.09) as analyzed by matched *t*-test and conditional logistic regression.

In a study of 1,031 cases of epithelial ovarian cancer and 2,411 controls, Bidoli et al [13] concluded that the intakes of micronutrients, including thiamin, in vegetables and fruits of

the subjects were inversely associated with the occurrence of ovarian cancer.

Ireson, Conway and Schwarzenbach [14] reported the effect of yeast on Ehrlich ascites tumor in mice. They fed 0.1ml yeast to each of 80 mice of equal sex and 0.1ml saline to another 80 mice of equal sex. After 14 days of feeding, Ehrlich ascites tumor cells were injected into the abdominal cavity. Abdominal fluid and its cellular count were then measured at the 7th day and the 14th day after inoculation. The average abdominal fluid volumes and cellular counts in yeast group were lower than those of the saline group by 37% and 53% after 7 days, and by 30% and 40% after 14 days. When injected the tumor cells into the groin of each mouse and weighed the solid tumors of at the 14th, 21st and 28th days after inoculation. The average tumor weights of 20 mice in each of the 3 yeast groups were 30%, 13%, and 9% lower than their corresponding saline groups. Since yeast is a major medicine in beriberi therapy, these results were applicable to the role of thiamin deficiency in cancer formation.

In a study of aberrant crypt foci (ACF), a biomarker of colon cancer in rats, Bruce et al [15] found that reduced thiamin in diets increased the number of ACF in colon of the rats. They fed sucrose-based diets containing thiamin 4.9, 1.6, or 1.0 mg/kg to 16 rats as controls, and 10 rats in each of two study groups. After 160 days, the average numbers of ACF were 1.14 +/- 1.17 and 2.60 +/- 1.02 for the two study groups.

Possible mechanism of thiamin deficiency on cancer formation

When thiamin is deficient, the activities of thiamin-dependent enzymes for transketolation, decarboxylation and dehydrogenation involved in glycolysis decrease. Some intermediates in carbohydrate metabolism may be accumulated due to metabolic blockage in different pathways, such as glycolysis bypass, acetone metabolism, and amino acid breakdown and/or removal failure. For example, the triose phosphates formed by normal glycolysis will rearrange their structure to form α -oxoaldehydes.

Thiamin deficiency also decreases glutathione concentration in blood cells and heart and thereby antioxidant activity for free radicals and detoxifying ability for α -oxoaldehydes decreases. Some metabolites would be excessively accumulated including reactive oxygen species, reactive nitrogen species, α -oxoaldehydes, advanced glycation end-products (AGEs) and some other detrimental substances in body fluids or some tissues [16]. They may be oncogenic:

- A. Prolonged elevated cellular free radicals may activate signal transduction pathways, including AP-1 and NF κ B, leading to the transcription of genes involved in cell growth. They also cause DNA damage, mutation, and modification of gene expression [17]. When bone fracture, large amounts of free radicals are generated [18]. This might be the case in our osteosarcoma patient previously reported.
- B. α -oxoaldehydes are also reactive compounds and adversely involved in multiple major pathologic processes,

including glucose auto-oxidation, DNA oxidation, lipid peroxidation, glycation with free amino groups of proteins and free radical formation [19]. They react with proteins forming adducts and DNA causing miscoding, point mutations and cytogenetic damages. If DNA damage cannot be repaired, cancer development would be likely.

C. After treating Wistar rats with N-methyl-N'-nitro-N-nitrosoguanidine, Takahashi et al [20] found glyoxal promoted the occurrence of adenocarcinoma in the pylorus of the glandular stomach, while methylglyoxal enhanced the incidence of hyperplasia in the pylorus of the rats. Nagao et al injected methylglyoxal subcutaneously to the rats and caused tumor at the injection site.

D. The highly reactive α -oxoaldehydes may react with proteins to form possibly genotoxic compounds, the AGEs, such as N-(epsilon)-carboxymethyl lysine, pentosidine and some else. AGEs might be involved in the enhanced cancer development in advanced kidney diseases [21].

Thiamin improves the anti-oxidant activity of glutathione system and thereby reduces free radicals. Practically, thiamin might be an indirect antioxidant. Thiamin suppressed the formation of methylglyoxal [22] and the production of AGEs in bovine retinal and human umbilical vein endothelial cells cultured under high glucose condition [23]. Its inhibitory effect on AGEs formation was even stronger than that of aminoguanidine. Therefore, thiamin may be critically important in preventing some aging related diseases, including cancer, hypertension, diabetes, arthropathy, cognitive disorders, etc.

As postulated by Thornalley [22], Brownlee [24], Hammes et al [25], Obrenovich and Monnier [26], thiamin blocks three major pathways of hyperglycemic damage and prevents diabetic complications. These include the hexosamine pathway, the advanced glycation end-products formation pathway, and the diacylglycerol-protein kinase C pathway as well as the inhibition of hyperglycemia-associated NF κ B activation. Their hypotheses indicate that pathological lesions caused by thiamin deficiency would be much more numerous than those described in classic beriberi, such as described in a booklet by this author [27].

Conclusion and suggestion

1. Physiologic thiamin therapy for some tumor and cancer is very effective and much less expensive as studied, however, its bothersome multiple injections should be updated.
2. It should be tried for every kind of space occupying lesions.

Disclosure: This paper is beneficial to all human beings without any conflict of interest to any body in any aspect.

References

1. Lee BY, Thurmon TF (1997) Nutritional disorders in a concentration camp. *Journal of American College of Nutrition*.16(4): 366-375.
2. Cascante M, Centelles JJ, Veech RL, Lee WN, Boros LG (2000) Role of thiamin (vitamin B1) and transketolase in tumor cell proliferation. *Nutr Cancer* 36: 150-154.
3. Boros LG, Brandes JL, Lee WN et al. (1998) Thiamin supplementation to cancer patients: a double edged sword. *Anticancer Res* 18: 595-602.
4. Lee BY, Yanamandra K, Bocchini JA (2005) Thiamin deficiency: a possible major etiology of some tumors? *Oncol Reports* 14: 1589-1592.
5. Z Ashe JA, Sweet RL, Hanberry BS, Ye S (2013) Linking vitamin B1 with cancer cell metabolism. *Cancer & Metabolism* 1: 16.
6. Hanberry BS, Berger R, Z Ashe JA (2014) High dose VB1 reduces proliferation in cancer cell lines analogous to dichloracetate. *Cancer Chemother Pharmacol* 73: 585-594.
7. Sweet RL, Z Ashe JA (2013) HIF1-alpha-mediated gene expression induced by VB1 deficiency. *Int J Vitam Nutri Res* 83(3); 188-197.
8. Luong KV, Nguyen LT (2013) The role of thiamin in cancer, possible genetic cellular signaling mechanisms. *Cancer Genomics Proteomics*; Jul-Aug 10: 169-185.
9. Tuynes AJ (1986) A case-control study on colorectal cancer in Belgium. Preliminary results. *Sozial und praventimedzin* 31: 81-82.
10. Slattery ML, Potter JD, Coates A et al. (1997) Plant foods and colon cancer: an assessment of specific foods and their related nutrients (United States). *Cancer Causes Control* 8: 575-590.
11. Jedrychowski W, Steindorf K, Popiela T et al. (2002) Alcohol consumption and the risk of colorectal cancer at low levels of micronutrient intake. *Med Sci Monit* 8: CR357-363.
12. Du S, Shi L, Zhang H, He S (1977) Relationship between dietary nutrient intakes and human prostate cancer. *Weisheng Yanjiu* 26: 122-125.
13. Bidoli E, La Vecchia C, Talamini R et al. (2001) Micronutrients and ovarian cancer: a case-control study in Italy. *Ann Oncol* 12: 1589-1593.
14. Ireson J, Conway GE, Schwarzenbach FH (1972) The effect of a complex yeast preparation, as a food supplement, on the growth of Ehrlich's ascites tumor in mice. *Eur J Cancer* 8: 159-166.
15. Bruce WR, Furrer R, Shangari N, O'Brich PJ, Medline A, Wang Y (2003) Marginal dietary thiamin deficiency induces the formation of colonic aberrant crypt foci (ACF) in rats. *Cancer Letter*; 20: 125-129.
16. Shangari N, Bruce WR, Poon R, O'Brien PJ. (2000) Toxicity of glyoxals - role of oxidative stress, metabolic detoxification and thiamin deficiency. *Biochem Soc Trans* 31(pt 6): 1390-1393.
17. Klaunig JE, Kamendulis LM (2004) The role of oxidative stress in carcinogenesis. *Annu Rev Pharmacol Toxicol* 44: 239-67.
18. Symons MC (1996) Radicals generated by bone cutting and fracture. *Free Radic Biol Med* 20: 831-835.
19. Thornalley PJ (1996) Review: Pharmacology of methylglyoxal: Formation, modification of proteins and nucleic acids, and enzymatic detoxification-A role of pathogenesis and antiproliferative chemotherapy. *General Pharmacology* 27: 565-573.
20. Takahashi M, Okamiya H, Furukawa F et al. (1989) Effect of glyoxal and methylglyoxal administration on gastric carcinogenesis in Wistar rats after initiation with N-methyl-N'-nitro-N-nitrosoguanidine. *Carcinogenesis* 10: 1925-1927.
21. Singh R, Barden A, Mori T, Beilin L (2001) Advanced glycation end-products: a review. *Diabetologia* 44: 129-146.
22. Thornalley PJ, Jahan I, Ng Rita (2001) Suppression of the accumulation of triosephosphates and increased formation of methylglyoxal in human red blood cells during hyperglycemia by thiamin *in vitro*. *J Biochem* 129: 543-549.
23. La Selva M, Beltramo E, Pagnozzi F, Bena E, Milinattie PA, Molinatti GM, Porta M (1996) Thiamin corrects delayed replication and decreases production of lactate and advanced glycation end products in bovine retinal and human umbilical vein endothelial cells cultured under high glucose condition. *Diabetologia* 96: 1263-1268.

24. Brownlee M (2001) Biochemistry and molecular cell biology of diabetic complications. *Nature* 414: 813-820.
25. Hammes HP, Du X, Edelstein D, Taguchi T, et al. (2003) Benfotiamine blocks three major pathways of hyperglycemic damage and prevents experimental diabetic retinopathy. *Nature Medicine* 9: 4-299.
26. Obrenovich ME, Monnier VM (2003) Vitamin B1 blocks damage caused by hyperglycemia. *Sci Aging Knowledge Environ* 10: PE6.
27. Lee BY, Bai J H (2017) Nutritional New Diseases and New Concepts. KF Times Group Inc, , West Vancouver, B.C. Canada.