

75-year-old man with a broken heart - survival of left ventricular free-wall rupture in completed myocardial infarction

Patiño S^{1*}
Carrero M²

^{1,2}Department of Internal Medicine, Mayagüez Medical Center, Hospital in Mayagüez

Abstract

Heart rupture is a major lethal complication of acute myocardial infarction (MI) and is almost exclusively seen as ST-elevation myocardial infarction (STEMI), with very rare cases reported for NSTEMI. We present a 75 y/o male who had free wall rupture in the apex, which caused acute tamponade after completed myocardial infarction and survived this lethal complication.

Introduction

Left ventricular free wall rupture (LVFWR) is an infrequent complication representing 2–4% but it is associated with a high mortality, usually as the result of rapid development of pericardial tamponade [1]. It accounts for 30% of all in-hospital deaths related to acute myocardial infarction [3,4,6]. Risk factors for LVFWR are advanced age, female gender, first-time myocardial infarction (MI) hypertension, and ST-segment elevation. We report a case of a 75-year-old man with ventricular wall rupture after myocardial infarction presenting acute cardiac tamponade. In this paper, we review an update on the clinical diagnosis and management of these cases.

Case Report

A 75-year-old man with past medical history of hypertension, type 2 diabetes mellitus, and hypothyroidism arrived at the emergency department complaining of severe oppressive retrosternal chest pain, 10/10 in intensity for approximately 30 minutes duration, which radiated into his jaw and left arm, and was associated with nausea and diaphoresis. He had three episodes of chest pain earlier that day of about 10 minutes each. A 12-lead electrocardiogram (ECG) showed Q waves and ST elevation in leads II, III, and aVF Figure 1. Cardiac enzymes were elevated; CK-MB 12.30 U/L, and troponin-I 2.840 ng/L. He was initially treated with dual antiplatelet therapy, high dose statins. Anticoagulation was achieved with enoxaparin 1 mg/kg every 12 hours. On the second day of his hospitalization due to recurrent chest pain he was transferred to our institution for coronary angiography. On arrival he was found hemodynamically unstable. He was sweating and lethargic. Physical examination revealed a man in obvious respiratory distress, his blood pressure was 70/40 mmHg, his heart rate was 110 beats / min, and an electrocardiogram showed sinus tachycardia Figure 2. Cardiac auscultation revealed muffled heart sounds no audible rub, no new murmurs with evident bounding jugular venous distension (JVD). The lung fields were clear to auscultation.

He was successfully intubated to protect airway in the presence of altered mental status. Intravenous fluid resuscitation with normal saline as well as vasopressors were needed in the setting of systemic

Article Information

Article Type: Case Report

Article Number: JCDM102

Received Date: 12th-January-2018

Accepted Date: 16th-January-2018

Published Date: 23rd-January-2018

***Corresponding author:** : Dr. Skarlet W. Patiño, Department of Internal Medicine, Mayaguez Medical Center, Ave. Hostos # 410, Mayagüez, PR 00681, USA. Tel: 703-986-4886; Email: skarletmd@gmail.com

Citation: Patiño S, Carrero M (2018) 75-year-old man with a broken heart - survival of left ventricular free-wall rupture in completed myocardial infarction. J Cardiovas Disea Medic 1:1 (06-11).

Copyright: © 2018 Patiño S, et al. This is an open-access article distributed under the terms of the Creative Commons Attribution License, which permits unrestricted use, distribution, and reproduction in any medium, provided the original author and source are credited.

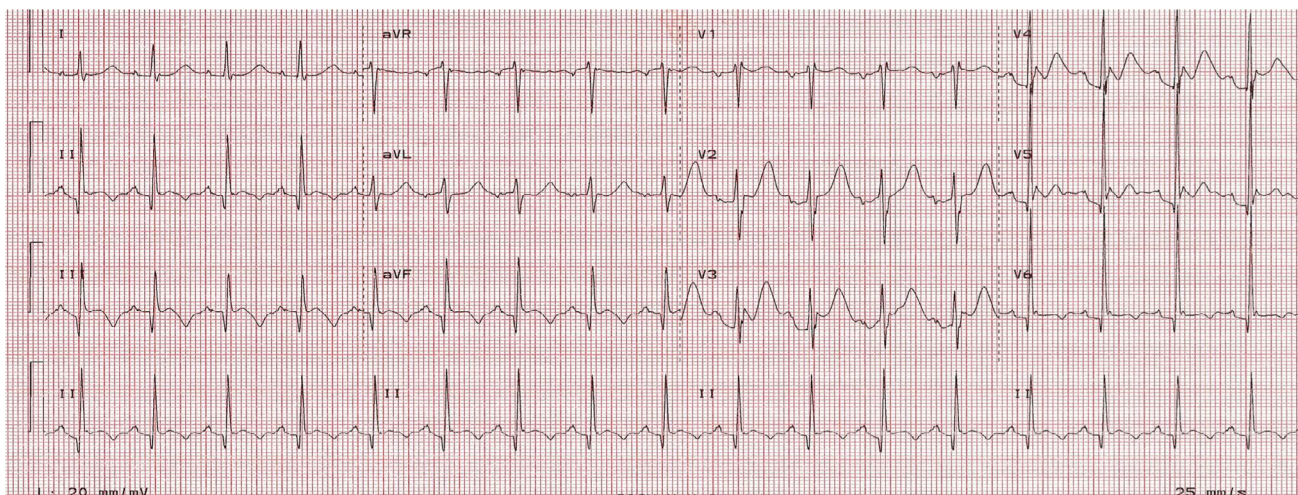


Figure 1: EKG: 2 mm ST elevation inferior leads with Q waves.

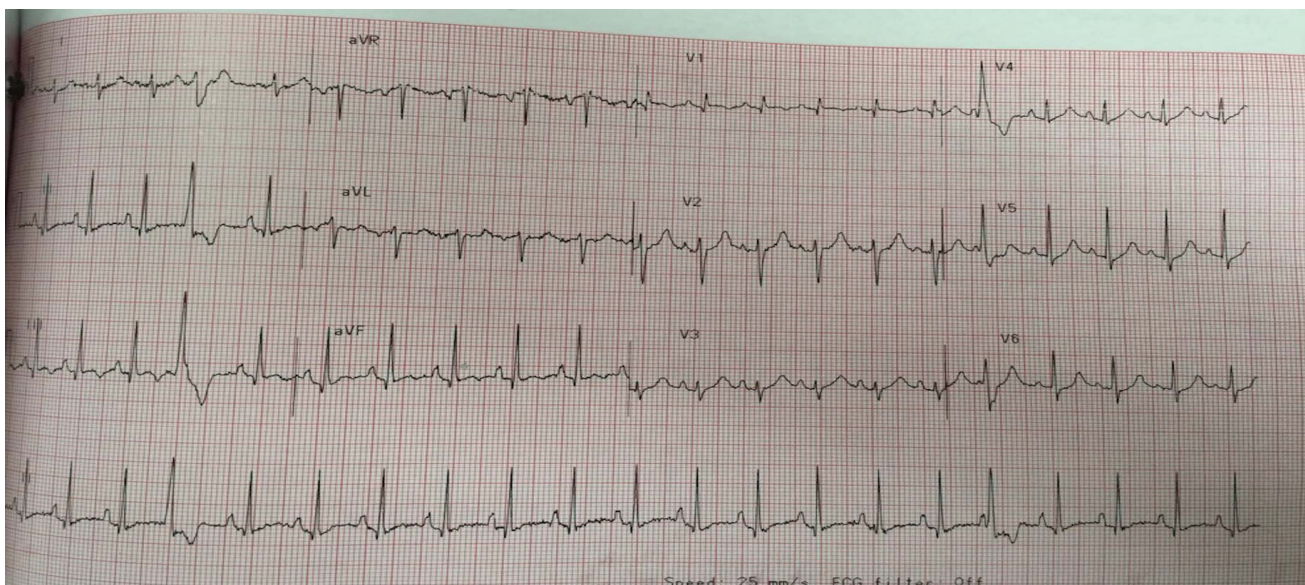


Figure 2: EKG: Sinus Tachycardia.

hypoperfusion. A 12-lead electrocardiography revealed sinus tachycardia, low-voltage QRS complexes with diffuse S-T segment elevation inferior leads with Q waves, and no electrical alternans. These clinical finding correlate with differential diagnosis of recurrent myocardial infarction, myocardial wall rupture and pulmonary embolism. Bedside Echocardiography showed global thinning of the left ventricle, diffuse global hypokinesia, a large pericardial effusion; a diagnosis of cardiac tamponade was established. Color flow Doppler imaging failed to identify an area of rupture Figure 3-5.

Computed Tomography scan of the heart with contrast revealed massive pericardial effusion and left ventricular free wall rupture with a hematoma Figure 6. The patient was resuscitated with intravenous fluids and inotropes and an urgent cardiothoracic surgery was performed. Bleeding from a myocardial tear at the apex of left ventricle was identified with several blood clots at the rupture site. Patient

underwent emergency mediastinal exploratory surgery, hematoma removal, and apex repair Figure 7. The patient recovered well after surgery and was discharged home 12 days following the operation.

This case demonstrates how left ventricular free wall rupture is not always fatal and that early diagnosis and high vigilance by clinicians for this condition can develop in a successful outcome.

Discussion

After the introduction of percutaneous coronary intervention, the incidence of left ventricular wall rupture (LVWR) decreased but remained approximately 1.7% [1-5]. HR occurs in patients with transmural myocardial infarction, which is almost exclusively ST-elevation myocardial infarction (STEMI). It carries a high mortality as a result of hemopericardium and cardiac tamponade [6]. Most publications focus on HR after transmural MI, with little or

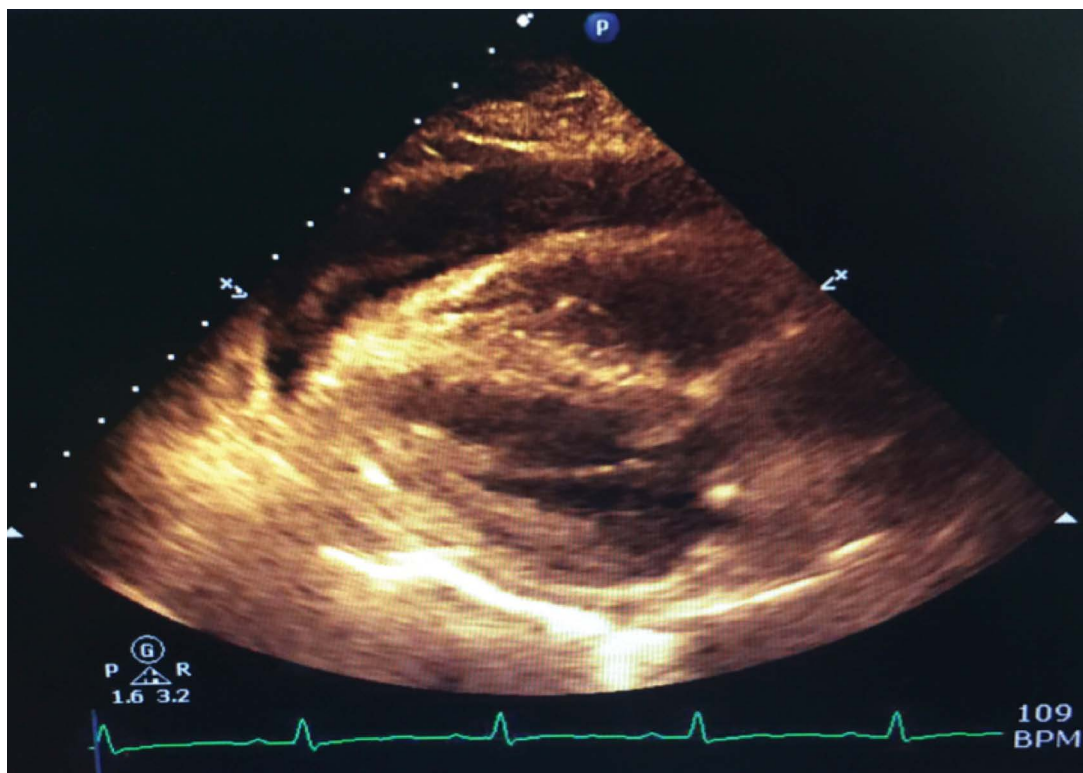


Figure 3: Echocardiography: global thinning of left ventricle.

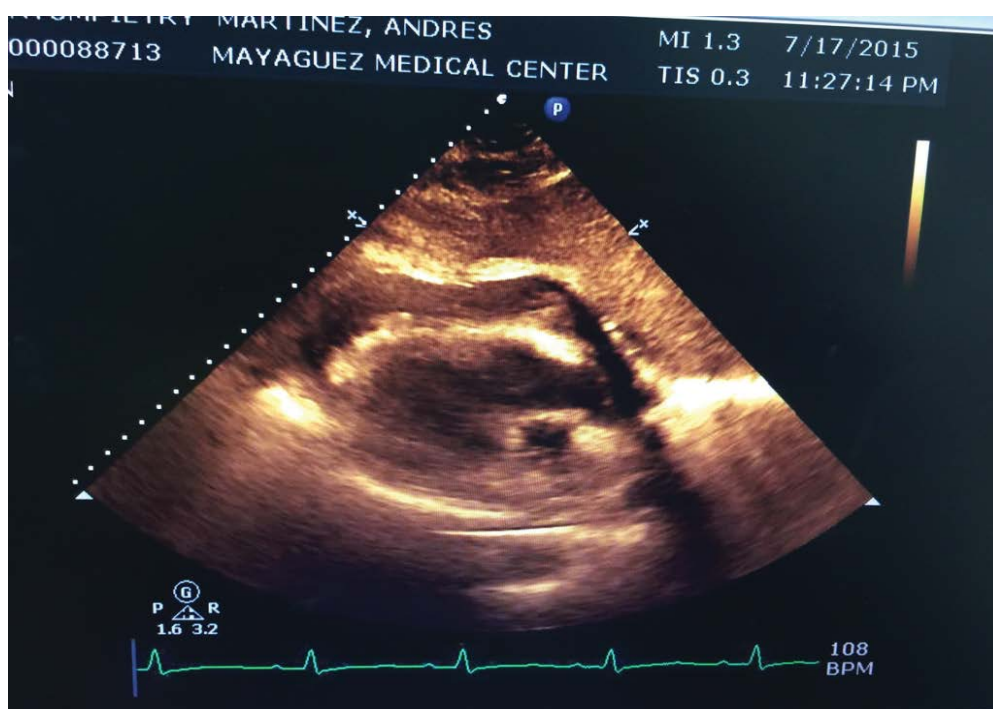


Figure 4: Echocardiography: diffuse global hypokinesia.

no information available for this complication in other types of acute coronary syndromes (ACS), and there have been very few reports of non-ST-elevation myocardial infarction (NSTEMI) resulting in this catastrophic complication. Following a clinical case presentation, we provide an update on the clinical presentation, diagnosis approach and the

management of this fatal condition.

The clinical characteristics of patients with free wall rupture occur in relatively elderly patients generally older than 55 years of age, female gender. In most cases following the first-time MI, transmural myocardial infarction with pronounced ST segment elevation with or without persistent

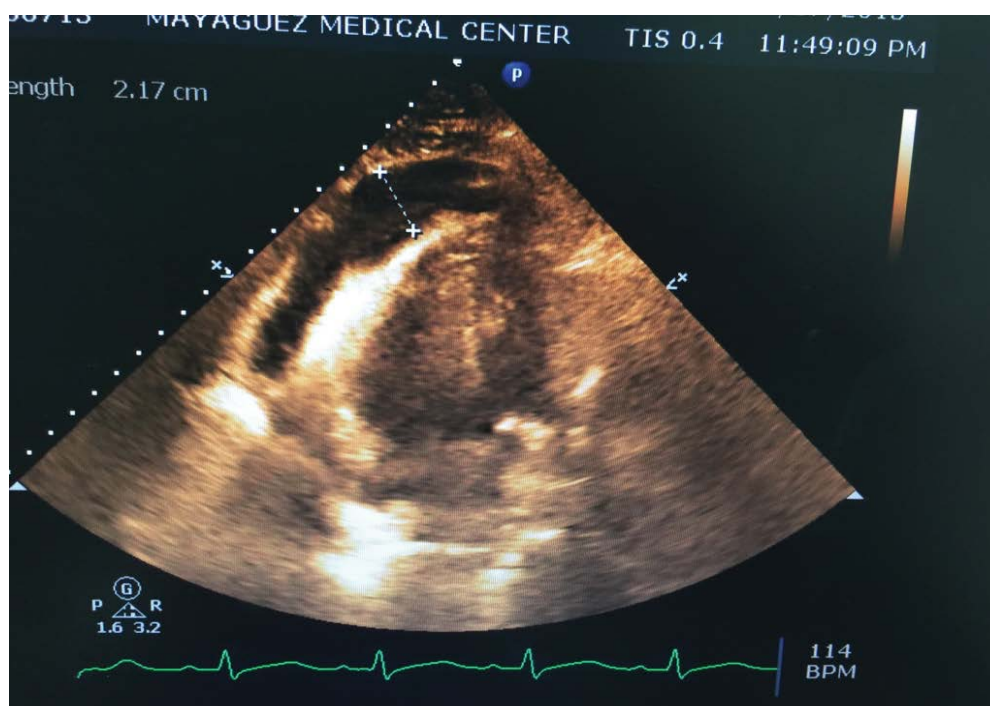


Figure 5: Echocardiography: cardiac tamponade physiology.

ST segment elevation on ECG [7,8]. In some cases, patients may also present with a prolonged episode of chest pain with hypotension that rapidly progresses to hemodynamic instability or sudden electromechanical dissociation on electrocardiogram, where the possibility of a free wall rupture is particularly high. Left ventricle free wall rupture occurs at three distinct intervals and most commonly occurs at the lateral wall [7].

The three distinct pathologic subsets are:

- **Type I** rupture early rupture occurs in the first 24 hours after a MI, associated to the use of fibrinolytic and becomes a full-thickness rupture.
- **Type II** rupture occurs 1 to 3 days after MI and is a result of erosion of the myocardium at the site of infarction.
- **Type III** rupture occurs more than 4 days after MI and is located at the border zone between infarcted and normal myocardium [8].

According to the type of presentation, free wall rupture may also be considered acute or subacute according to clinical presentations. The acute type presents with sudden cardiac death caused by severe hypotension following detrimental bradyarrhythmia, electromechanical dissociation secondary to acute pericardial tamponade.

The subacute form may account for up to 30% of all cases of in-hospital free wall rupture [9]. It is usually accompanied with a moderate to severe pericardial effusion without hemodynamic compromise identified in echocardiogram. It is also frequently associated with sinus bradycardia and jugular venous congestion which could be temporarily reversed by resuscitative maneuvers and subsequent surgical repair [10]. The goal of therapy is to diagnose the

problem early and perform emergency open-heart surgery to correct the rupture. Qian et al. [11] has developed a risk model with seven independent baseline clinical predictors: female sex, advanced age, anterior MI, delayed admission, heart rate, elevated white blood cell count and anemia.

Although there is generally insufficient time for thorough diagnostic testing in the management of patients with acute rupture, transthoracic echocardiography is the emergent test of choice. Echocardiography typically demonstrates a pericardial effusion with findings of cardiac tamponade. These findings include: Right atrial and Right ventricle diastolic collapse, dilated inferior vena cava, marked respiratory variations in mitral and tricuspid inflow. Swan-Ganz Pulmonary Artery catheter may reveal hemodynamic signs of tamponade, with equalization of the right atrium, right ventricle diastolic pressures, and pulmonary capillary wedge pressures.

Emergency pericardiocentesis may be performed immediately in patients with tamponade and severe hemodynamic compromise while arrangements are being made for transportation to the operating room [12,13]. The procedure carries with it considerable risk since as the intrapericardial pressure is relieved, communication is reestablished between the intra and extra ventricular spaces, often leading to further bleeding into the pericardium. Medical management has no role in the treatment of these patients, except for the use of vasopressors to maintain blood pressure temporarily as the patient is rushed to the operating room [8].

Cardiac rupture continues to be a catastrophic complication of myocardial infarction and is responsible for 30% of hospital deaths related to acute myocardial

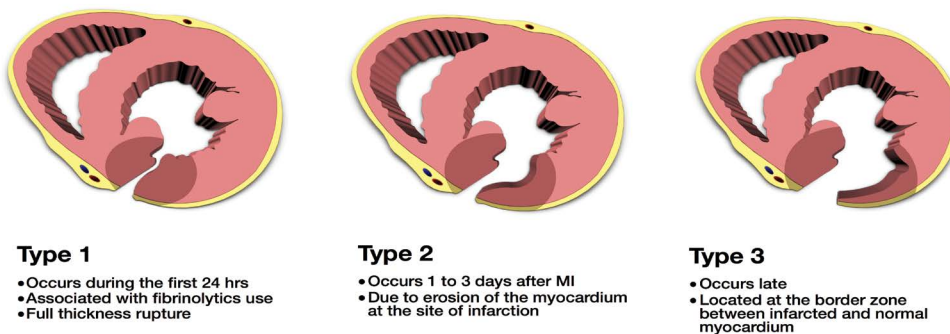


Figure 6: Computed Tomography scan with contrast revealed massive pericardial effusion and sealed left ventricular free wall rupture with a hematoma.

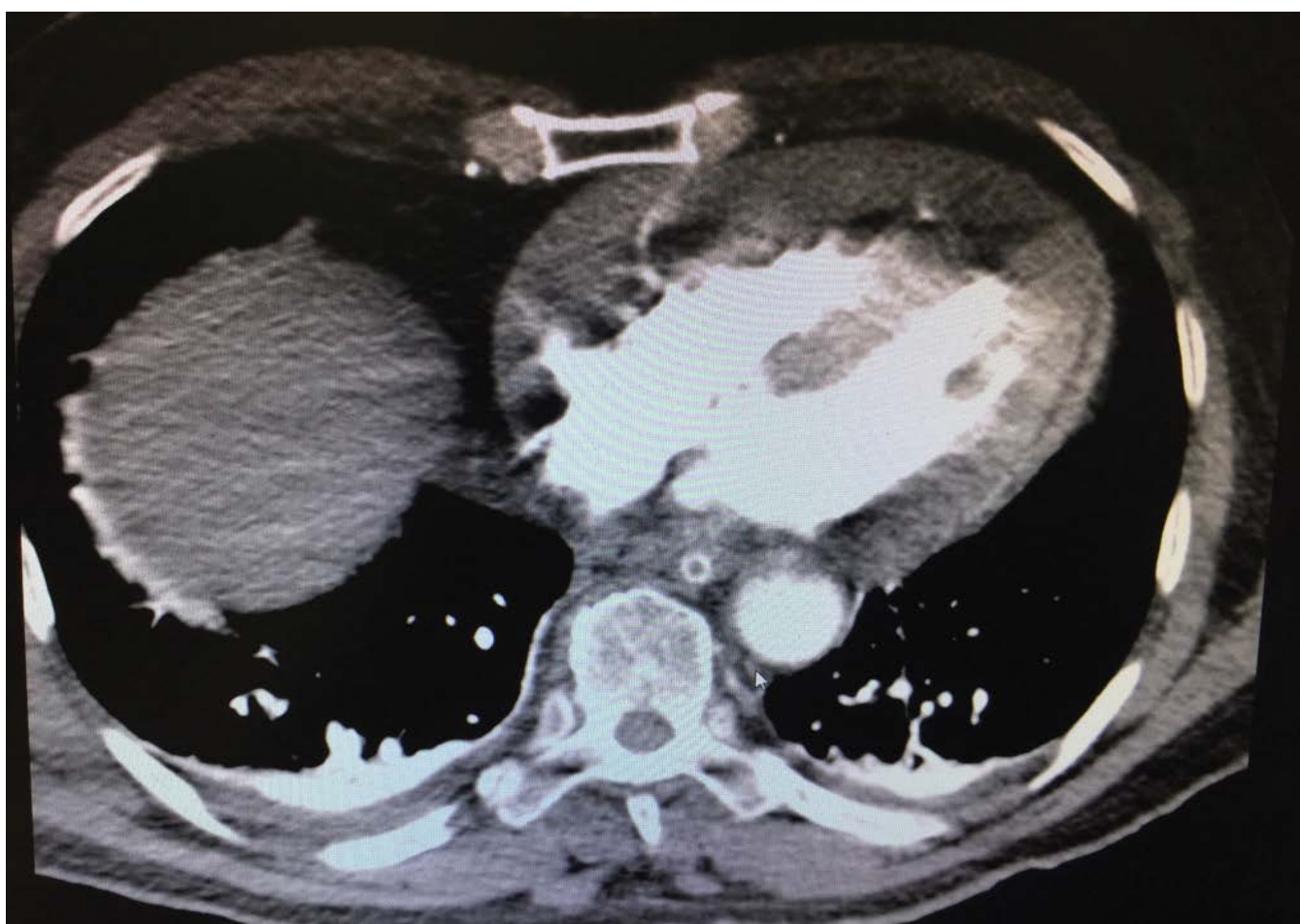

Figure 7: Description: Perioperative image of myocardial rupture at 2:30 AM.

infarction. Transmural infarction, secondary to acute total coronary occlusion appears to be a substrate for left ventricle wall rupture. Over the past several decades, the incidence of heart rupture has decreased with the development of Percutaneous Coronary Intervention. Therefore, early revascularization will prevent these complications and ensure long-term survival.

Acknowledgment

A special thanks to Dr. Milton Carrero for his full support in submitting this case for presentation and also to Dr. Javier Acevedo, Dra. Myriam Garcia and all of those at Mayagüez Medical Center who participated in this case's challenging management.

This case report was presented during a poster

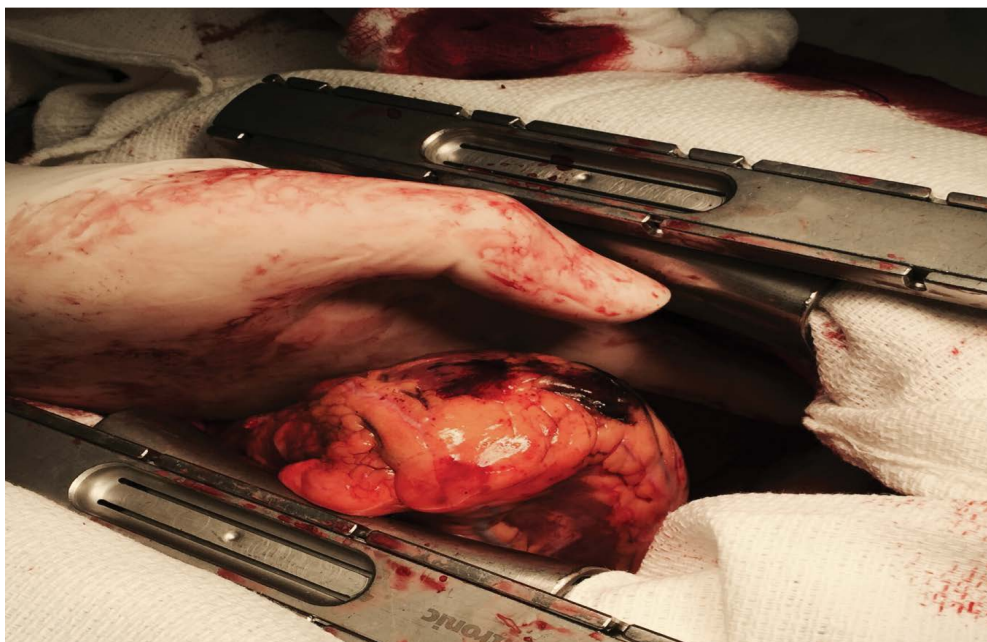

Figure 8: Description: Types of free wall rupture according to time of occurrence or form of presentation.

presentation at the American College of Physicians' (ACP) Annual Meeting, Puerto Rico Chapter and the 22nd World Cardiology Conference in Rome Italy 2017.

References

1. Lopez-Sendon J, Gurfinkel EP, Lopez de Sa E, Agnelli G, Gore JM, et al. (2010) Factors related to heart rupture in acute coronary syndromes in the Global Registry of Acute Coronary Events. *Eur Heart J.* 31(12): 1449–56.
2. Driesman A, Hyder O, Lang C, Stockwell P, Poppas A, et al. (2015) Incidence and Predictors of Left Ventricular Thrombus After Primary Percutaneous Coronary Intervention for Anterior ST-Segment Elevation Myocardial Infarction. *Clin Cardiol.* 38(10): 590–7.
3. Figueras J, Cortadellas J, Soler-Soler J (2000) Left ventricular free wall rupture: clinical presentation and management. *Heart.* 83(5): 499–504.
4. Davierwala PM, Leontyev S, Verevkin A, Rastan AJ, Mohr M, et al. (2016) Temporal Trends in Predictors of Early and Late Mortality After Emergency Coronary Artery Bypass Grafting for Cardiogenic Shock Complicating Acute Myocardial Infarction. *Circulation.* 134(17): 1224–37.
5. Formica F, Mariani S, Singh G, D'Alessandro S, Messina LA, et al. (2018) Postinfarction left ventricular free wall rupture: a 17-year single-centre experience. *Eur J Cardio-Thoracic Surg.* 53(1): 150–6.
6. Honda S, Asami Y, Yamane T, Nagai T, Miyagi T, et al. (2014) Trends in the Clinical and Pathological Characteristics of Cardiac Rupture in Patients With Acute Myocardial Infarction Over 35 Years. *J Am Heart Assoc.* 3(5): e000984–e000984.
7. Davies R, Robich M, Coady M (2014) Complications of Myocardial Infarction. In: Yuh D, Vricella L, Yang S, Baumgartner W, editors. *John Hopkins Cardiothoracic Surgery.* 2nd ed. New York, NY: McGraw-Hill.
8. Grass AW, Brener SJ (2014) Complications of Acute Myocardial Infarction [Internet]. Cleveland Clinic Center for Continuing Education.
9. Jacquier A, Thuny F, Jop B, Giorgi R, Cohen F, et al. (2010) Measurement of trabeculated left ventricular mass using cardiac magnetic resonance imaging in the diagnosis of left ventricular non-compaction. *Eur Heart J.* 31(9): 1098–1104.
10. O'Rourke R, Dell'Italia LJ (2004) Diagnosis and management of right ventricular myocardial infarction. *Curr Probl Cardiol.* 29(1): 6–47.
11. Qian G, Jin R, Fu Z, Yang Y, Su H, et al. (2017) Development and validation of clinical risk score to predict the cardiac rupture in patients with STEMI. *Am J Emerg Med.* 35(4): 589–93.
12. Nasir A, Gouda M, Khan A, Bose A (2014) Is it ever possible to treat left ventricular free wall rupture conservatively? *Interact Cardiovasc Thorac Surg.* 19(3): 488–93.
13. Purcaro A, Costantini C, Ciampani N, Mazzanti M, Silenzi C, et al. (1997) Diagnostic criteria and management of subacute ventricular free wall rupture complicating acute myocardial infarction. *Am J Cardiol.* 80(4): 397–405.

Citation: Patiño S, Carrero M (2018) 75-year-old man with a broken heart - survival of left ventricular free-wall rupture in completed myocardial infarction. *J Cardiovas Disea Medic* 1:1 (06-11).