

Extracranial and Diffuse Bone Marrow Metastases from Anaplastic Oligodendroglioma: A Case Report and Review of the Literature

Evangelia Razis^{1*}
Avraam Assi¹
Albert Huang¹
Georgios Rigakos¹
Sotirios Papadopoulos¹
Savvas Papadopoulos²
Efimia Vrakidou³
Constantinos Dardoufas⁴
Christos Mourmouris⁵
Stefanos Lampropoulos¹
Panagiotis Nomikos⁶

¹Third Department of Medical Oncology (A.A, A.H, G.R, Sot.P, S.L and E.R)

²Pathology Department (Sav.P)

³Hematology Department (E.V)

⁴Radiation Oncology Department (C.D)

⁵Radiology Department (C.M)

⁶Neurosurgery Department (P.N), Hygeia Hospital, 4 Erythrou Stavrou Str. & Kifisias Av. 151 23 Marousi, Athens, Greece

Abstract

Extracranial metastases from anaplastic oligodendroglioma are very rare. We present a 53 year old male patient who developed extracranial progression and bone marrow metastases from anaplastic oligodendroglioma nearly nine years from the primary diagnosis. He presented with sudden deterioration of consciousness, lethargy, left periorbital swelling and thrombocytopenia, and underwent an MRI of the brain which revealed a left frontal lesion protruding through the orbital cavity impinging on the eye ball. The lesion was subsequently resected, and the histology revealed progression into an anaplastic oligodendroglioma. Furthermore, the patient developed pancytopenia and iliac crest bone marrow biopsy was diagnostic for metastatic, immunohistochemically confirmed anaplastic oligodendroglioma.

Keywords: Oligodendroglioma, Anaplastic, Extracranial, Metastasis, Pancytopenia.

Introduction

Oligodendrogliomas are defined as tumors consisting primarily of neoplastic oligodendrocytes and comprise 1.1% of all primary brain tumors. Their highest incidence occurs between the third and fifth decades of life with a median age at diagnosis of 43 years, although they have also been reported in children and adolescents. The most common sites of location are the frontal and temporal lobes [1]. Oligodendrogliomas may remain silent for many years with the most common presenting symptoms at the time of diagnosis being headache, seizure and focal neurologic deficits. As tumors progress, symptoms vary based on tumor location, size, and rate of tumor growth. Oligodendrogliomas can be divided further into low-grade and anaplastic, the latter characterized by high cellularity, conspicuous cytologic atypia, mitotic activity and, in some cases, microvascular proliferation and necrosis (Grade III). Compared with astrocytic tumors, oligodendroglial tumors more often harbor favorable molecular markers, such as co-deletion of the chromosome arms 1p and 19q and mutations in isocitrate dehydrogenase (IDH). Usually, they spread by local growth and infiltration. Extracranial metastasis is very rare, despite its malignant nature. In a review of 116 patients with extracranial metastases from primary brain tumors, only 7 were caused by oligodendrogliomas (5.25%) [2].

Article Information

Article Type: Case Report

Article Number: JCCRT117

Received Date: 27 March, 2019

Accepted Date: 03 April, 2019

Published Date: 05 April, 2019

***Corresponding author:** Evangelia Razis, MD, PhD, Director. Third Department of Medical Oncology, Hygeia Hospital, 4 Erythrou Stavrou Str. & Kifisias Av. 151 23 Marousi, Athens, Greece. Tel: +30 210 686 7165, +30 210 686 7071; Email: [erazis\(at\)hygeia.gr](mailto:erazis(at)hygeia.gr)

Citation: Razis E, Assi A, Huang A, Rigakos G, Papadopoulos S, et al (2018) Extracranial and Diffuse Bone Marrow Metastases from Anaplastic Oligodendroglioma: A Case Report and Review of the Literature. J Clin Case Rep Trials. Vol: 2, Issu: 1 (01-05).

Copyright: © 2018 Razis E, et al. This is an open-access article distributed under the terms of the Creative Commons Attribution License, which permits unrestricted use, distribution, and reproduction in any medium, provided the original author and source are credited.

The most frequent metastatic site is bone and bone marrow followed by lymph nodes, liver, lung and scalp [3, 4, 6]. Furthermore, the median time to diagnosis of extracranial metastasis is 34 months and the median survival from the initial diagnosis is 51 months respectively [5]. So far, the exact pathogenic mechanisms implicated in the development of extracranial dissemination remain ill-defined. We report a case of anaplastic oligodendroglioma that progressed extracranially and metastasized to the bone with diffuse bone marrow infiltration.

Case report

A 53 year old man presented with epileptic crises in February 2013. He had been diagnosed with oligodendroglioma in 2004 for which he had had multiple craniotomies and radio/chemotherapy cycles with local recurrences and remissions. In December 2012, resection of a left frontotemporal lesion was performed which revealed relapse of anaplastic oligodendroglioma. The molecular analysis revealed 1p19q co-deletion, IDH1 mutation and MGMT (O⁶-methylguanine-DNA methyltransferase) promoter methylation. Adjuvant radiotherapy and chemotherapy consisting of Procarbazine, lomustine and Vincristine (PCV regimen) were administered, followed by an MRI in May 2013 showing abnormal contrast uptake in the margins of the excised tumor located in the left frontal lobe. Physical examination in July 2013 revealed diminished concentration and left periorbital swelling. A brain MRI showed progression with a left frontal lesion protruding through the orbital cavity invading the orbital fossa. Craniotomy and gross total resection of the lesion followed on September 13, 2013.

Upon macroscopic examination of the material there were 3 tissue specimens measuring together 5,5 x 3,5 cm. These were partially covered by fibroid tissue, partially solid grayish-white and hemorrhagic on the cut surface. The diagnosis was anaplastic oligodendroglioma with neoplastic infiltration of the bone forming the orbital fossa. Tumor cells were hypercellular

with intense pleomorphism, vacuolated background, high mitotic activity and nuclear atypia, with areas of microvascular proliferation and necrosis. Immunohistochemically the tumor cells were strongly positive for epidermal growth factor receptor (EGFR) and P53, with focal expression of the glial fibrillary acidic protein (GFAP) and MIB1 (Mindbomb E3 Ubiquitin Protein Ligase-1) positivity in more than 50% of the tumor cells consistent with a high proliferative rate.

The patient left the hospital in a much better condition, but he deteriorated again a few days later. He was re-admitted in October 2013 for lethargy and swelling in his left eye resulting in exophthalmos. A new MRI of the brain showed relapse once again with a lesion extending from the left cranial fossa to the sphenoid sinus and the left orbital fissure (Figure 1). He started treatment with systemic therapy consisting of Bevacizumab 10mg/kg every 14 days along with Volumetric Modulated Arc Radiotherapy (VMAT), a total dose of 38,5 Gy over 11 days.

In the meantime, gradually progressing bilateral muscle weakness of the lower extremities developed, leading eventually to paraplegia and the patient was admitted for further evaluation. At this point, an MRI of the thoracic and lumbar spine showed diffuse abnormal signal intensity in all the thoracic and lumbar vertebrae, with an epidural lesion at the level of the 4th and 5th thoracic and the 5th lumbar vertebrae, causing spinal cord compression (Figure 2). A CT guided fine needle aspiration confirmed metastatic anaplastic oligodendroglioma. Neurological work up confirmed cord compression as the cause of paraplegia.

In addition, progressively worsening pancytopenia of prolonged duration, led us to perform a diagnostic bone marrow aspiration in November 2013 which yielded a “dry tap” but the associated bone marrow biopsy revealed replacement of the myeloid spaces by the neural neoplasm.

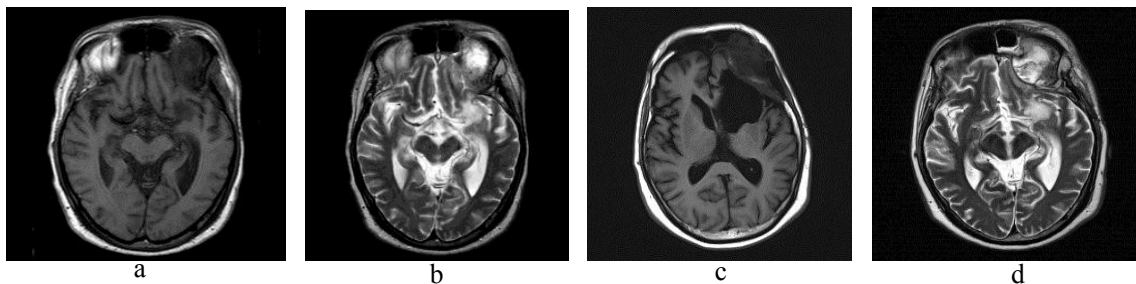


Figure 1: MRI scan showing axial images of a left frontal mass protruding through the left orbital fossa in (a) T1 and (b) T2 MR weighted images before surgical intervention and after (c) T1 and (d) T2 progression of disease.

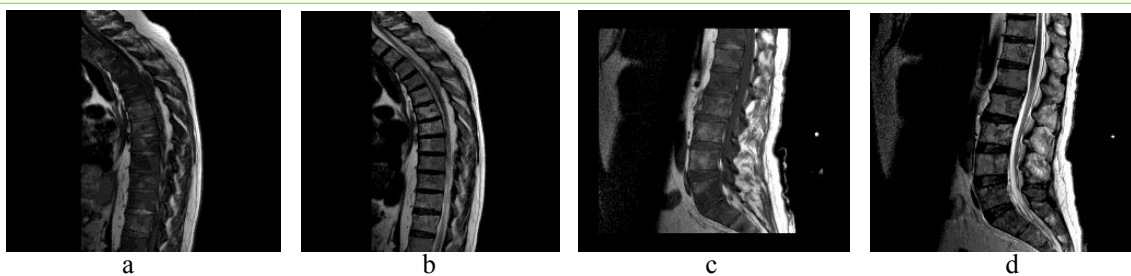


Figure 2: MRI scan showing sagittal sections of the thoracic and lumbar spine with several metastatic vertebral lesions in T1-weighted (a, c) and T2-weighted (b, d) images.

Immunohistochemically, the tumor cells were positive for glial fibrillary acidic protein (GFAP), tumor protein p53, synaptophysin and S100 protein, while being negative for cytokeratin-8 (CK8), Wilms tumor protein (WT1), human melanoma black protein-45 (HMB45), epidermal growth factor receptor (EGFR), cluster of differentiation protein-34 (CD34), cluster of differentiation protein-138 (CD138) and myeloperoxidase staining. The Ki-67 labelling index was 10–15%.

Consequently, the patient started radiotherapy to the thoracic spine (30 Gy delivered over 11 days) and continued with Bevacizumab in a dose of 15mg/kg every 3 weeks. Unfortunately, lower extremity motor strength was not recovered, and he was transferred home for palliative care.

Eventually, the patient's general condition and neurological status deteriorated. He died of tumor progression 9 ¼ years after the original diagnosis.

Discussion

Extra neural metastasis from oligodendroglioma is an extremely rare event with only a few cases reported worldwide. A systematic review of the literature found a total of 38 papers reporting 47 cases of bony metastasis from oligodendrogliomas between 1951 and 2017 [3,4,6-42].

Despite the continuous advances in the fields of pathology and molecular biology in the previous decades, the exact mechanisms involved in the spread of extracranial metastases remain ill-defined.

Oligodendrogliomas are the least likely to metastasize among different types of neural tumors. A review of 116 glioma cases in the literature showed that the most common metastasizing tumor type was glioblastoma multiforme (41.4%) followed by medulloblastoma (26.7%), ependymoma (16.4%), astrocytoma (10.3%) and finally oligodendroglioma (5.25%) [2].

The combined analysis of 32 cases of metastatic oligodendrogliomas showed that the most frequent metastatic site was bone and bone marrow (97%), followed by lymph nodes (33%) [3,4,6].

The possible mechanisms involved in the process of metastasis indicate hematologic and lymphatic routes of transmission, though a cerebrospinal fluid route could also be involved [2,9,43].

It has been observed that distant metastases follow craniotomy in the majority of cases. According to this analysis nearly 96% of extracranial metastases have occurred after surgical excision of the primary tumor, suggesting infiltration of tumor cells into surgical defects and extracranial blood vessels [2]. Craniotomy breaches the brain's innate defense systems, enabling tumor cells to gain entry to both the meningeal and the vertebral venous systems. Furthermore, in some cases, tumor cells may progress extracranially through mechanical escape routes such as ventriculoatrial shunts [44].

So far, 3 distinct patterns of metastatic spread in oligodendrogliomas have been recognized. Macdonald et al detected 2 distinct patterns of metastatic spread. Pattern 1 is characterized by local spread first appearing in the surrounding scalp and in

ipsilateral cervical lymph nodes after multiple craniotomies. The tumor may subsequently disseminate to other organs. In pattern 2, patients present with multiple bone metastases at the outset after craniotomy and failure of multimodal therapy with no evidence of initial local or regional spread [14]. A third pattern has been added by Garner et al in which cerebrospinal fluid is the route of spread resulting in intradural deposits [18].

Although the above observations potentially explain the incidence of extraneural dissemination in cases where mechanical defects take place, the access to extraneural sites is not enough to produce metastasis. The role of local factors in the host organ must also be important, further allowing its colonization from tumor cells.

On the other hand, distant metastases have also been observed in cases where no craniotomies had been performed [16]. The reported cases of spontaneous metastatic spread and the overall rarity of the metastatic incidence render the exact mechanisms obscure. Several initial theories trying to explain why metastases are so uncommon have been generally discredited. These include inability of neural tissue to grow outside of the central nervous system, lack of lymphatics in the brain and collapse of thin-walled cerebral veins by advancing tumor [45]. It has been postulated that the absence of intracranial lymphatic vessels poses a significant barrier to tumor spread, while the intracerebral veins are thin walled or encased in dura and therefore collapse ahead of advancing tumor [46]. The idea that brain tumors present earlier and progress to death faster, thus allowing less time for the development of metastases tends to be more accepted nowadays [6,18,47]. It is suggested that metastatic deposits are probably a late event in the natural history of high grade gliomas.

Another theory suggested by Pansera suggests that as the brain parenchyma has little connective tissue stroma, metastatic clones are not selected for their ability to invade fibrous connective tissue and so they are incapable of growing extracranially [48].

In our case, the possible route for infiltration of the bone forming the left orbital fissure could be attributed to the previous craniotomies. Our patient fits well in the 1st pattern described from Macdonald et al in which bone and bone marrow dissemination follows local spread of the tumor in the surrounding scalp near the previous craniotomy. Of note had we been more aware of the rare cases of metastases, we might have detected these earlier thus preventing him from becoming paraplegic. Thus, we publish this case because we feel that the neuro-oncologic community needs to be aware of this possibility. Additionally, we emphasize the necessity of bone marrow biopsy in oligodendroglioma patients experiencing prolonged or profound hematologic toxicity (Figure 3,4).

Conclusion

We reported a case of anaplastic oligodendroglioma with extracranial progression and bone marrow metastases nearly nine years from the initial diagnosis. To our knowledge this is one of few case reports reported in the literature. The exact mechanisms through which extracranial progression occurs remain obscure although disruption of the normal brain barriers through surgical intervention or cerebrospinal fluid, vascular

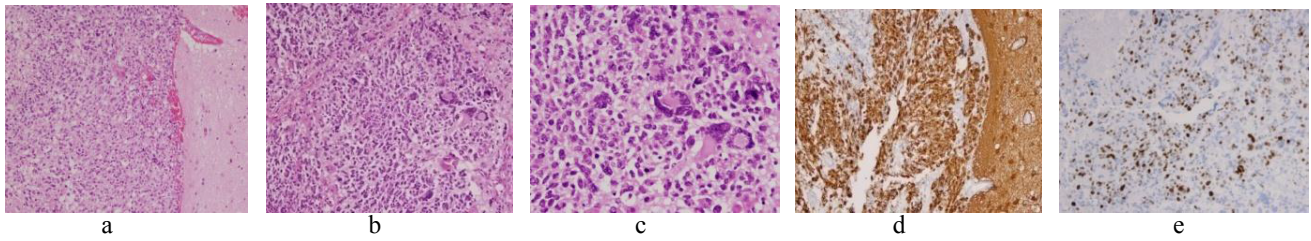


Figure 3: Photomicrographs of the tumor specimens obtained from the left frontal lesion invading the orbital fossa, showing hypercellular tumor cells with various degrees of pleomorphism and atypia, mitoses and vacuolated background (a, b, c respectively, H&E). Immunocytochemistry pictures are positive for glial fibrillary acidic protein (d) and Ki-67 respectively with proliferating index >50% (e).

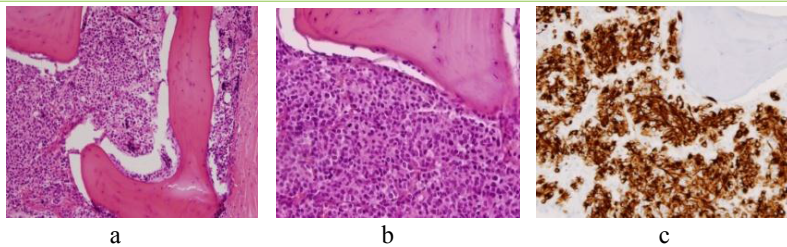


Figure 4: Photomicrographs of the tumor specimens obtained from the bone marrow biopsy revealing infiltration and replacement of the myeloid spaces from oligodendroglial cells (a - b, H&E respectively). Immunocytochemistry is positive for glial fibrillary acidic protein (c).

and lymphatic escape seems to play a significant role in the metastatic process.

Conflict of Interest statement

Each author certifies that he or she has no commercial associations (eg, consultancies, stock ownership, equity interest, patent/licensing arrangements, etc) that might pose a conflict of interest in connection with the submitted article.

Funding statement

The authors certify that the submitted article was not supported neither related to any kind of funding.

References

- Ostrom QT, Gittleman H, Fulop J, Liu M, Blanda R et al. (2015) CBTRUS Statistical Report: Primary Brain and Central Nervous System: Tumors Diagnosed in the United States in 2008-2012. *Neuro Oncol* 17.
- Liwnicz BH, Rubinstein LJ (1979) The pathways of extraneural spread in metastasizing gliomas: a report of three cases and critical review of the literature. *Hum Pathol* 10: 453-467.
- Li G, Zhang Z, Zhang J, Jin T, Liang H, et al. (2014) Occipital anaplastic oligodendroglioma with multiple organ metastases after a short clinical course: a case report and literature review. *Diagnostic Pathology* 9: 17.
- Patrick R, Maloney, Vitor Nagai Yamaki, Ravi Kumar, Derek Johnson, Christopher Hunt, et al. (2017) Osteosclerosis Secondary to Metastatic Oligodendroglioma. *Rare Tumors* 9: 6837.
- Mazza E, Belli C, Terreni M, Doglioni C, Losio C, et al. (2013) Breast metastases from oligodendroglioma: An unusual extraneural spread in two young women and a review of the literature. *Critical Reviews in Oncology / Hematology* 88: 564-572.
- Zustovich F, Della Puppa A, Scienza R, Anselmi P, Furlan C, et al. (2008) Metastatic oligodendrogliomas: a review of the literature and case report. *Acta Neurochir (Wien)* 150: 699-702.
- James, T. G. and Pagel, W (1951) Oligodendroglioma with extracranial metastases. *Br J Surg* 39: 56-65.
- Spataro J, Sacks O (1968) Oligodendroglioma with remote metastases. Case report. *J Neurosurg* 28: 373-379.
- Smith DR, Hardman JM, Earle KM (1969) Metastasizing neuroectodermal tumors of the central nervous system. *Journal of Neurosurgery* 31: 50-58.
- Eade, O. E, Urlich, H (1971) Metastasising gliomas in young subjects. *J. Pathol* 103: 245-256.
- Schuster H, Jellinger K, Gund A, Regele H (1976) Extracranial metastases of anaplastic cerebral gliomas. *Acta Neurochir (Wien)* 35: 247-259.
- Ordonez NG, Ayala AA, Leavens ME (1981) Extracranial metastases of oligodendroglioma: report of a case and review of the literature. *Neurosurgery* 8: 391-395.
- Nakamura O, Watanabe T, Nomura K, Nakajima T (1985) Diffuse bone marrow metastasis of an anaplastic oligodendroglioma. *No Shinkei Geka* 13: 903-909.
- Macdonald DR, O'Brien RA, Gilbert JJ, Cairncross JG (1989) Metastatic anaplastic oligodendroglioma. *Neurology* 39: 1593-1596.
- Gerrard GE, Bond MG, Jack AS (1995) Bone marrow infiltration by a parietal lobe grade III oligodendroglioma. *Clin Oncol (R Coll Radiol)* 7: 321-322.
- Yanagawa Y, Miyazawa T, Ishihara S, Takiguchi H, Shima K et al. (1996) Pontine glioma with osteoblastic skeletal metastases in a child. *Surg Neurol* 46: 481-494.
- Dawson T P (1997) Case report. *Neuropathology and Applied Neurobiology* 23: 516-520.
- Garner J, Morcos Y, Bari M (2002) Extradural cord compression due to metastatic oligodendroglioma. *J Neurooncol* 58: 71-75.
- Pectasides D, Halikia A, Visvikis A, Bountouroglou N, Tzikas I, et al (2002) Successful management of extracranial metastases from cerebral high-grade oligodendroglioma: report of a case with literature review. *J BUON* 7: 273-276.
- Anand M, Kumar R, Jain P, Gupta R, Ghosal N, et al (2003) Metastatic anaplastic oligodendroglioma simulating acute leukaemia. *Acta Cytol* 47: 467-469.
- Giordana MT, Gasverde S, Balteri I (2004) Bone metastasis of oligodendrogliomas: clinical and molecular genetic study. *J Neurooncol* 66: 265-271.
- Sharma A, Agarwal A, Sharma MC, Anand M, Agarwal S, et al. (2003) Bone marrow metastasis in anaplastic oligodendroglioma. *Int J Clin Pract* 57: 351-352.

23. Choon A, Roepke JE (2004) Importance of immunohistochemical staining in metastatic anaplastic oligodendroglioma. *Arch Pathol Lab Med* 128: 489-490.
24. Morrison T, Bilbao JM, Yang G, Perry JR (2004) Bony metastases of anaplastic oligodendroglioma respond to temozolomide. *Can J Neurol Sci* 31: 102-108.
25. Al-Ali F, Hendon AJ, Liepman MK, Wisniewski JL, Krinock MJ et al (2005) Oligodendroglioma metastatic to bone marrow. *AJNR Am J Neuroradiol* 26: 2410-2414.
26. Merrell R, Nabors LB, Perry A, Palmer CA (2006) 1p/19q chromosome deletions in metastatic oligodendroglioma. *J Neurooncol* 80: 203-207.
27. Bruggers C, White K, Zhou H, Chen Z (2007) Extracranial relapse of an anaplastic oligodendroglioma in an adolescent: case report and review of the literature. *J Pediatr Hematol Oncol* 29: 319-322.
28. Uzuka T, Kakita A, Inenaga C, Takahashi H, Tanaka R, et al. (2007) Frontal anaplastic oligodendroglioma showing multi-organ metastases after a long clinical course. Case report. *Neurol Med Chir (Tokyo)* 47: 174-177.
29. Noshita N, Mashiyama S, Fukawa O, Asano S, Watanabe M, et al. (2010) Extracranial metastasis of anaplastic oligodendroglioma with 1p19q loss of heterozygosity—case report. *Neurol Med Chir (Tokyo)* 50: 161-164.
30. Krijnen JL, Fleischeur RE, van Berkel M, Westenend PJ (2010) Metastatic oligodendroglioma: a case report and incidence in The Netherlands. *Clin Neuropathol* 29: 141-146.
31. Kural C, Pusat S, Sentürk T, Seçer Hİ, İzci Y (2011) Extracranial metastases of anaplastic oligodendroglioma. *J Clin Neurosci* 18: 136-138.
32. Wu Y, Liu B, Qu L, Tao H (2011) Extracranial skeletal metastasis in anaplastic oligodendroglioma: case report and review of the literature. *J Int Med Res* 39: 960-967.
33. Cordiano V, Miserocchi F, Storti M (2011) Bone marrow metastases from anaplastic oligodendroglioma presenting with pancytopenia and hypogammaglobulinemia: a case report. *Tumori* 97: 808-811.
34. Greene J, Cadoo K, Ti J, O'Donnell N, Allcutt D, et al. (2013) 1p19q co-deleted oligodendroglioma metastatic to bone. *Clin Neuropathol* 32: 139-141.
35. Tanaka Y, Nobusawa S, Ikota H, Yokoo H, Hirato J, et al. (2014) Leukemia-like onset of bone marrow metastasis from anaplastic oligodendroglioma after 17 years of dormancy: an autopsy case report. *Brain Tumor Pathol* 31: 131.
36. Liu, H., Lu, X. and Thakral B (2016) A rare presentation of anaplastic oligodendroglioma metastatic to bone marrow, mimicking blast cells. *Br J Haematol* 174: 344-344.
37. Demeulenaere M, Duerinck J, DU Four S, Fostier K, Michotte A, et al. Bone Marrow Metastases from a 1p/19q Co-deleted Oligodendroglioma - A Case Report. *Anticancer Res* 36: 4145-4149.
38. Yuan Jian, Wen Gao, Yin Wu, Yanchen Li, Yong Zhang, Guangzhong Yang, et al. Oligodendroglioma metastasis to the bone marrow mimicking multiple myeloma: A case report. *Oncology Letters* 12: 351-355.
39. Sequeira M, Rosinha A (2016) P08.51 Extracranial metastasis of oligodendroglioma. *Neuro-Oncology* 18: 53.
40. Sun Q, Xu R, Xu H, Wang G, Shen X, et al. (2017) Extracranial metastases of high-grade glioma: the clinical characteristics and mechanism. *World Journal of Surgical Oncology* 15: 181.
41. Lavrador JP, Oliveira E, Tortosa F, Ortiz S, Pimentel J, et al. (2017) Metastatic grade III oligodendroglioma revealed by refractory thrombocytopenia. *J Neurosurg Sci* 61: 547-550.
42. Ambinder EB, Rowe SP (2017) A Case of Anaplastic Oligodendroglioma With Extensive Extraneural Metastases Imaged With FDG PET. *Clin Nucl Med* 42: 968-970.
43. Schweitzer T, Vince GH, Herbold C, Roosen K, Tonn JC (2001) Extraneural metastases of primary brain tumors. *J Neurooncol* 53: 107-114.
44. Wakamatsu T, Matsuo T, Kawano S, Teramoto S, Matsumura H (1972) Extracranial metastasis of intracranial tumor—review of literatures and report of a case. *Pathology International* 22: 155-169.
45. Subramanian A, Harris A, Piggott K, Shieff C, Bradford R (2002) Metastasis to and from the central nervous system—the 'relatively protected site'. *Lancet Oncol* 3: 498-507.
46. Dodge OG (1974) The Spread of Tumours in the Human Body. *British Journal of Cancer* 29: 343-344.
47. Frappaz D, Jouvot A, Pierre GS, Giammarile F, Guyotat J, et al. (2001) Lack evidence of osteo-medullary metastases at diagnosis in patients with high grade gliomas. *J Neurooncol* 52: 249-252.
48. Pansera F, Pansera E (1992) An explanation for the rarity of extraaxial metastases in brain tumors. *Med Hypotheses* 39: 88-89.